

MORPHOLOGICAL AND BIOMETRICAL STUDY ON ADULT RAMS, BUCKS, AND BULLS TESTIS IN DUHOK PROVINCE

SALEEM ABDULLAH SOFI

Dept. of Theriogenology, physiology and anatomy, College Veterinary Medicine,
University of Duhok, Kurdistan region-Iraq

(Received: November 7, 2021; Accepted for Publication: January 23, 2022)

ABSTRACT

Fifteen paired testes of apparently healthy adult Local rams, bucks, and bulls were collected from the slaughterhouse in the Duhok province, to compare their gross morphology and biometrical parameters. Each testis position, form, structures, size, and relationship to other elements of the region were recorded. The testes of three species were oval, and the largest was in bull and the smallest in buck. The average weight, length, circumference, volume and density of both testicles in the ram, buck, and bull varied significantly ($p \leq 0.05$) from each other. The mean thickness and width of the left and right testicles in the three species didn't differ significantly. The ram testicular density and volume were significantly different ($p \leq 0.05$) in comparing biometrical values between the left and right testes, The length, volume, and density of the left and right testes differed significantly ($p \leq 0.05$) in the buck. The circumference, volume, and density of the left and right testes were significantly different ($p \leq 0.05$) in bulls, whereas the other values did not statistically different. The tunica albuginea was soft and grayish red in rams and bucks, but was a dense blue-gray membrane in bulls. The parenchyma layer of the testis revealed creamy white in both ram and buck but was yellow to creamy orange in the bull. In conclusion, this study has shown the similarities and differences in terms of gross morphology, morphometry between the testes of ram, buck, and bull.

KEYWORD: Ram, Buck and Bull ,Testis, Tunica vaginalis, Tunica albuginea , Mediastinum.

1- INTRODUCTION

Testes are endocrine and exocrine glands that emit male sex hormones and male gametes (spermatozoa). Testis vary in shape and size between animals and within a breed. Sheep testes are oval in shape and weigh between 80 and 300 grams. The testis weight is determined by the breed, the amount of food consumed, and, most importantly, the breeding season (Mukasa Mugerwa et al. 1986; Galmessa et al. 2000).

Testicular volume measurement is an essential criteria in the prediction of spermatogenesis, evaluation of testis functions, and the diagnosis of a variety of diseases that affect testicular growth and development. (Sakamoto et al., 2007; Karaman et al., 2005; Al Salim et al. 1995; Sakr & Shalaby, 2012; Al-Damegh, 2012). any changes in testis measurements indicates spermatogenesis and tissue mass alterations (Paltiel et al.2002).

There is little information about the morphology and histology of local ram testes. In several aspects, the reproductive systems of

various species differ. Furthermore, the testes differ in shape, size, and position between species.

Each testicle in the horse and dog has a nearly horizontal long axis and attached to the wall of the abdomen close to the superficial inguinal ring. The bull and small ruminant testes are nearly vertical. In a one-humped Camel bull, it lays obliquely with its long axis going cranio-ventrally. (Mahmud *et al.*, 2015; Dyce *et al.*, 2010; Aspinall and 'Reilly, 2005). Adult bull testicular size varies in length from 10 to 12 cm and from 6 to 8 cm in diameter (Ball and Peters, 2004). Certain animals' testes (horses, dogs, tomcats, and one-humped Camel bulls) have an elliptical shape with a convex and smooth lateral surface. Both the ventral and dorsal surfaces were nearly straight and convex. (Mahmud *et al.*, (2015); Aspinall and Reilly, (2005); Budras and Röck,(2009) found that the anterior and posterior extremities were rounded. Each testis is covered by the tunica vaginalis, made up of two layers: an outer layer that surrounds the inside of the scrotum and an inner layer that covers the

testis, spermatic cord, and epididymis for each testis..

The purpose of this research was to evaluate the anatomical characteristics and biometrical data of mature rams, bucks, and bulls left and right testes.

2.MATERIALS AND METHODS

This study used fifteen paired of testes from healthy adult rams, bucks, and bulls (five samples per species). These animals were presented to the abattoir in Duhok province. The breeders' records and the dentition were used to establish the age of each animal. The genital tracts were immediately transported to the laboratory and processed as soon as possible.

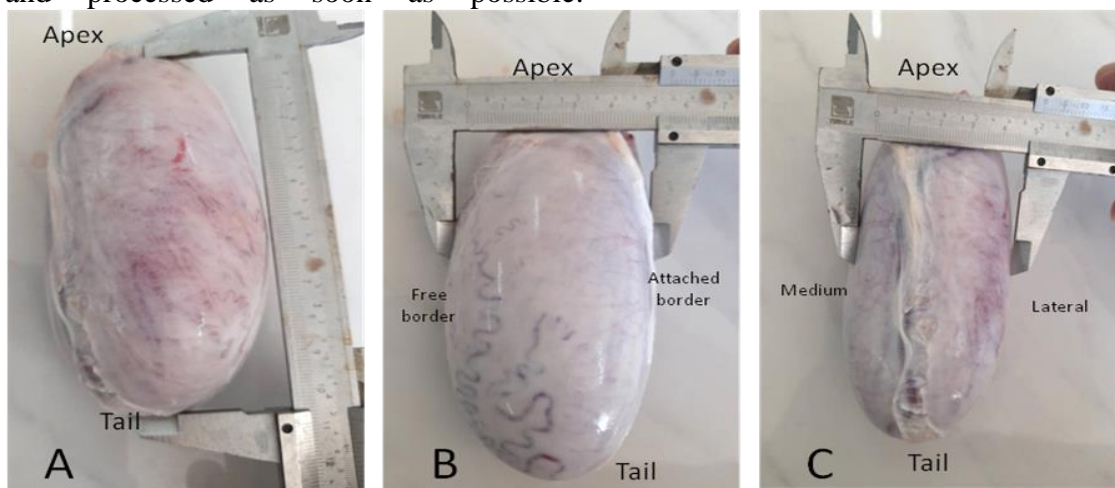


Fig. (1): shows the methods of measuring testes. A- length . B- Thickness c- Width. In bull.

Testicular circumference was measured by using a portion of string applied at the larger diameter and calculated on a scale (Ibrahim et al., 2012). Photographs of the testes were made using a digital camera. Testicular volume (TV) was measured by the water displacement technique using the Archimedes principles. The average testicular density is measured as Testes density = Testes weight (g) / Testes volume (cc) (Ibrahim et al., 2012). All of the data was examined using the Statistical Package for the Social Sciences (SPSS). To evaluate the degree of significant difference ($P \leq 0.05$) in mean values between each species' left and right testes, as well as between the three species, the Students' t-test and one-way analysis of variance were employed (ANOVA). (Steel and Torry, 1996).

Following the collection, gross features of the testes were examined and recorded. The epididymus were separated from each testis using a sterile blade, and various testicular gross features and parameters were measured for the right and left testicles separately. The average testicular weight (g) was measured (using a sensitive balance). The length (cm), thickness (cm) and width (cm) were measured using a vernier caliper. The length of the testes was measured from the apex to the tail; thickness was measured from the free border to the attached border of the epididymus; and the width was measured from the lateral to the medium surface of the testis (Fig. 1).

3.RESULTS

Adult ram, buck, and bull testicles are located between the thighs' cranial surfaces in the inguinal area, with a vertical and pendulous extended neck. Externally, all three species studied (ram, buck, and bull) had oval-shaped testis (Fig. 2). The bull's testes are the largest of the three species tested, while the bucks are the smallest. Furthermore, the medial and lateral surfaces had a convex and flattened look, respectively, with lateral surfaces communicating with the scrotum's septum. The open margins of the testes were almost convex, while the epididymis attached border was virtually straight.

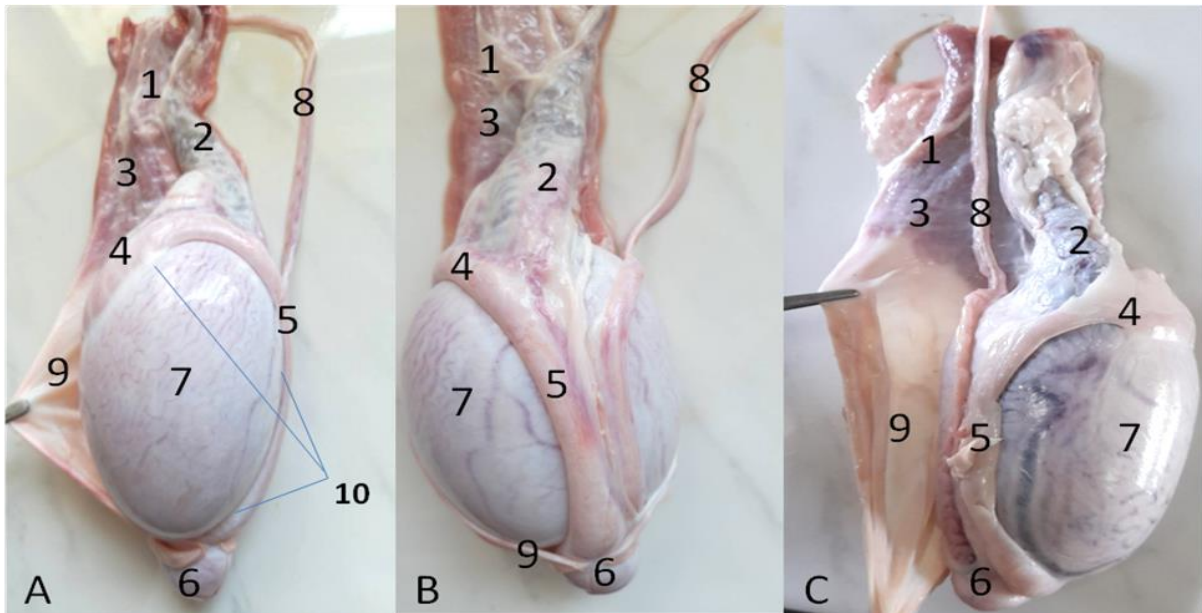


Fig. (2): Shows the A-Testis of Ram. B- Testis of a buck. C-Testis of bull . 1- Spermatic cord .2- Pampiniform plexus.3- Cremaster muscle.4- Head of epididymis 5- Body of epididymis .6- Tail of epididymis .7- Tunica albugenia .8- Vas deferens (ductus deference). 9- Tunica vaginalis. 10- Ligaments of epididymis.

Epididymis was firmly connected to the associated testis border and seemed to slightly overrun the lateral surface. The head is the expanded front end of the testis that is linked via connective tissue and serous membrane to the testis (Fig. 1, 2). The tail was a somewhat larger posterior end that was joined to the body by a narrow section between them that was less tightly held by the thin serous membrane. Furthermore, It generates a compartment beneath the epididymis on the side., which is known as the sinus of epididymis (Fig.2). The tail continued as a ductus deferens, and a small ligament arising from a thick fold of the tunica vaginalis was linked to the posterior extremity of the testis. (Fig. 1, 2). The tunica virginal's,

which is the internal layer of the membrane contrary to the connecting side of the testis, covered the majority of the testis surface, leaving a free area where the spermatic cord's veins and nerves reached the testis. (Fig. 2, 3). The tunica albuginea is a fibrous tissue covering the testis that is soft and grayish red in rams, darker in bucks, and dense blue grey membrane in bulls (Fig.2). The testis parenchyma was creamy white in both ram and buck, but were yellow to creamy orange in bull (Fig. 3). In all three species, the mediastinum of the testis appeared as a jellylike structure, and it became wider when it reached near to the apex of the testes (Fig.3).

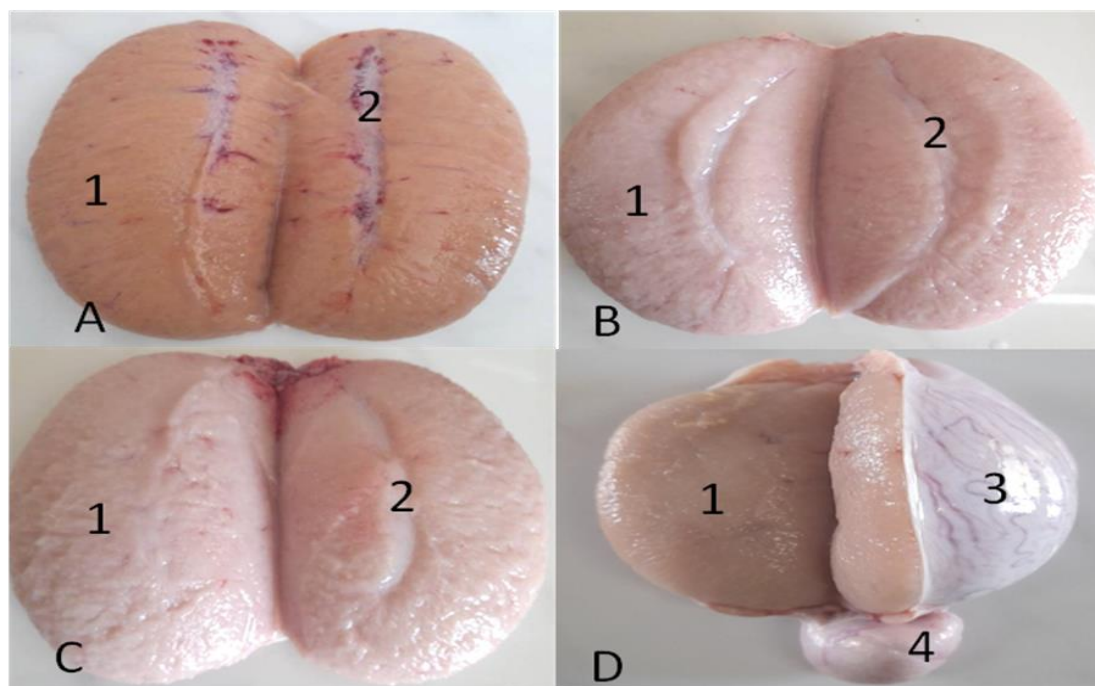


Fig. (3): Shows the testis of : A- Bull, B- Buck and C and D - Ram (parenchymal view). 1-Testicular parenchyma 2- Mediastinum 3- Tunica albugenia 4- Tail of epididymis.

The average of the weight, length, thickness, width, circumference, volume, and density of left testicular ram, buck and bull were (145.6 ± 3.91 gm, 139.4 ± 3.64 gm and 196.8 ± 2.77 gm), (9.3 ± 0.22 cm, 8.66 ± 0.19 cm and 11.24 ± 0.37 cm), (5.48 ± 0.19 cm, 5.5 ± 0.15 cm and 5.62 ± 0.14 cm), (4.7 ± 0.122 cm, 4.62 ± 0.083 cm and 4.76 ± 0.151 cm), (16.3 ± 0.44 cm, 15.46 ± 0.45 cm and 16.84 ± 0.11 cm), (132.4 ± 1.14 ml, 125.8 ± 0.83 ml and 171 ± 2.23 ml) and (1.096 ± 0.037 g/cm³, 1.102 ± 0.031 g/cm³ and 1.164 ± 0.023 g/cm³) respectively (Table, 1).

The average of the weight, length, thickness, width, circumference, volume, and density of the right testicular of the ram, buck and bull were (148.6 ± 1.14 gm, 141.2 ± 1.3 gm and 199.6 ± 3.50 gm), (9 ± 0.21 cm, 8.14 ± 0.11 cm and 10.94 ± 0.16), (5.4 ± 0.25 cm, 5.48 ± 0.27 cm and 5.56 ± 0.11 cm), (4.76 ± 0.151 cm, 4.66 ± 0.0114 cm and 4.8 ± 0.158 cm), (15.8 ± 0.57 cm, 15.04 ± 0.20 ml and 16.56 ± 0.15 cm), (128.8 ± 1.30 ml, 120.4 ± 1.67 ml and 162 ± 1.92 ml) and (1.148 ± 0.008 g/cm³, 1.168 ± 0.025 g/cm³ and 1.226 ± 0.0219 g/cm³) respectively (Table, 2).

The biometric data of the left and right testicular weight, length, circumference, and volume vary significantly ($P \leq 0.05$) between these species. After further separation, the meanings were found to be substantially different ($P \leq 0.05$) from one another. The mean testicular density of bulls differed considerably ($P \leq 0.05$) from that of rams and bucks. The biometrical values of left and right testicular thickness and width between three species, however, showed no variations (Table 1, 2). The ram testicular density and volume were substantially different ($P \leq 0.05$) when the biometrical values of the left and right testes were compared, but other parameters were not statistically different. The length, volume, and density of the left and right testes differed considerably ($P \leq 0.05$) in the buck, whereas the other values didn't differ significantly. The size, volume, and density of the left and right testes substantially differed ($P \leq 0.05$) in the bull, but the other values did not significantly vary (Table 1, 2).

Table (1): Mean \pm SD of testicular parameters of the left testis in ram, buck and bull.

Measurements	Ram	Buck	Bull
Testicular weight (g)	145.6 \pm 3.91 ^b	139.4 \pm 3.64 ^c	196.8 \pm 2.77 ^a
Testicular length (cm)	9.3 \pm 0.22 ^b	8.66 \pm 0.19 ^c	11.24 \pm 0.37 ^a
Testicular thickness (cm)	5.48 \pm 0.19 ^c	5.5 \pm 0.15 ^c	5.62 \pm 0.14 ^c
Testicular width (cm)	4.7 \pm 0.122 ^c	4.62 \pm 0.083 ^c	4.76 \pm 0.151 ^c
Testicular circumference(cm)	16.3 \pm 0.44 ^b	15.46 \pm 0.45 ^c	16.84 \pm 0.11 ^a
Testicular volume (ml)	132.4 \pm 1.14 ^b	125.8 \pm 0.83 ^c	171 \pm 2.23 ^a
Testicular density (g/cm ³)	1.096 \pm 0.037 ^b	1.102 \pm 0.0311 ^b	1.164 \pm 0.023 ^a

a, b, and c: Means (\pm SD) within a row, indicating that distinct superscript letters are substantially different ($P \leq 0.05$).

Table (2): Mean \pm SD of testicular parameters of the right testis in ram, buck and bull.

Measurements	Ram	Buck	Bull
Testicular weight (g)	148.6 \pm 1.14 ^b	141.2 \pm 1.3 ^c	199.6 \pm 3.50 ^a
Testicular length (cm)	9 \pm 0.21 ^b	8.14 \pm 0.11 ^c	10.94 \pm 0.16 ^a
Testicular thickness (cm)	5.4 \pm 0.26 ^c	5.48 \pm 0.27 ^c	5.56 \pm 0.11 ^c
Testicular width (cm)	4.76 \pm 0.151 ^c	4.66 \pm 0.114 ^c	4.8 \pm 0.158 ^c
Testicular circumference(cm)	15.8 \pm 0.57 ^b	15.04 \pm 0.20 ^c	16.56 \pm 0.15 ^a
Testicular volume (ml)	128.8 \pm 1.30 ^b	120.4 \pm 1.67 ^c	162.2 \pm 1.92 ^a
Testicular density (g/cm ³)	1.148 \pm 0.008 ^b	1.168 \pm 0.025 ^b	1.226 \pm 0.0219 ^a

a, b, and c: Means (\pm SD) within a row, indicating that distinct superscript letters are substantially different ($P \leq 0.05$).

4-DISCUSSION

The ability to quantify spermatogenesis and testicular activity using in vivo testicular measurements is a possibility (Sakamoto et al., 2007; Karaman et al., 2005). Scrotal diameter, testicular volume and form are the key selection for the reproductive ability in young beef cattle (Hahn et al., 1969; Silva et al., 2011).

The total sperm production was highly associated with these characteristics (Hahn et al. 1969). Sperm is the male reproductive cell, and it takes roughly 49 days to produce (7 weeks). The shape of testicles in ram is thought to be an excellent indicator of sperm-producing capabilities. Epididymus tail palpation is a good way to determine sperm reserves. Moreover, a large, hard tail strongly indicates good storage, whereas a small, soft tail would indicate the opposite (Aqeel et al., 2017).

The testis morphological characteristics and biometrical values in ram, buck, and bull were described in this study. The outward appearance and position of the mature ram, buck and bull testis were determined by this study. The shape, coloration, and orientation of the testes in

this study agree with previous studies in one-humped camels (Skidmore, 2000), sheep, and goats (Dyce et al., 2010).

The testis of the adult local bull were the largest, whereas the testis of the adult local buck were the smallest. This outcome is consistent with those previously reported (Mahmud et al., 2015; Andreussi et al., 2014). According to Akpa et al. (2012) and Etim (2015), any physical variables that can be measured are closely associated with the ability of the sperm to fertilize, which can be used as an assessment of sperm quality. The size of reproductive organ and the animal's physiological health might affect the production of semen.

The results of the current study mean testis weight are inconsistent with those of earlier studies (Ahemen & Bitto, 2007; Ragi et al., 2016). The weight and volume of the testicle revealed in this research were lower ($P \leq 0.05$) than those formerly reported in South African Doper rams (406 g and 378 mm³, respectively). Furthermore, this study findings revealed that the testicular weight of the mature buck was higher ($P \leq 0.05$) than those found by others (WGemeda and Workale mahu, 2017). These variances developed may be due to the genetic differences. According to Brito et al. (2004), heavy-weight testicles generate more

spermatozoa than light-weight testicles. As they possessed a high number of heavier sertoli cells that produced an excessive number of sperm as compared to testes with fewer sertoli cells (Sarma, 2012). In summery the testis biometrics are used to measure the animal sexual viability.

The ram testis weights were heavier than the buck testis in this study. The presence of endocrine cells, seminiferous tubules, and sertoli cells, as well as a larger amount of sperm, was verified by this finding. This conclusion is in line with the findings recorded by (Ibrahim et al., 2012). In addition to the above finding, the average volume of testicles in rams was considerably bigger ($P \leq 0.05$) than that of the bucks in this study. The variation in both interior and exterior dimensions of the male genitalia is thought to be a good predictor of sperm generation levels per ejaculate and its depends on sperm generation capacity (Riviers and Williams, 1984).

The current finding results are agree to that reported by El-Jack (1980) in one-humped camels, He stated that due to a larger pampiniform plexus on the left side, the right testicle is smaller than the left. The results obtained here on the local ram testes weight, which indicated that the right testis weighs was larger than those in the left, the result agree with the findings of reported by Ott *et al.* (1982) in sheep. Who reported that the left testis was 10% larger than the right testis On subsequent examinations. agrees to the present results are studies conducted on cattle and buffaloes by (Ahmed ,1984; Ahmed *et al.*, 1985;Purbey and Choudhury, 1985, and Ali ,1989).

This study showed that the testes volume, which indicated that the left testis volume was greater than the right, agreed with the finding of Gitaindro et al. (2014), who reported that the volume was always larger in the left testis than in the right one in pubertal bulls.

The mean testicular weight of the left and right in both rams and buck obtained in this research is close to that reported by Aqeel et al. (2017) in AL-Najaf AL-Ashraf but higher than the 134.48 g reported by Ahemen and Bitto (2007) In Nigeria, the West African dwarf ram is categorized as a small breed of indigenous sheep, thus this difference might be due to genetics (Osinowo, 1990).

5.CONCLUSION

This study describes the essential values for gross morphology and morphometry features in mature local rams, bucks, and bulls, as well as some differences and similarities between the three species. The findings of this study can be used as a research baseline for these native animals as well as for comparative testicular architecture in other animals.

6-REFERENCES

- Ahemen, T., and Bitto ,I .I. (2007). Sperm production rate, Gonadal and extra gonadal sperm reserves of the West African Dwarf rams in Makurdi. Conf. of Nig. Soc. for Anim. Prod. pp 99-101.
- Ahmad, M., Latif, M., Ahmad, M., Khan, I. H. Ahmad, N., and Anzar, M. (1985). Postmortem studies in infertile buffalo bulls. Anatomical and microbiological findings. Vet. Res.,117(5):104-9.
- Ahmad, N.(1984).Studies on the postnatal development of the reproductive organs in Nili Ravi buffalo calves. M.Sc. Thesis, Faisalabad – Pakistan, Dept. of Animal Reproduction, University of Agriculture.
- Akpa, G.N., Ambali, A.L., and Suleiman, I.O. (2012). Relationships between semen cation concentration, semen characteristics, testicular measurement and body conformation trait in Red Sokoto goat Nature and Science, 11(7):94.
- Al Salim, A., Murchison P. J.,Rana, A., Elton R. A., and Hargreave, T. B.(1995). Evaluation of testicular volume by three orchidometers compared with ultrasono graphic measurements. British journal of urology., 76(5):632-5.
- Al-Damegh, M. A.(2012). Rat testicular impairment induced by electromagnetic radiation from a conventional cellular telephone and the protective effects of the antioxidants vitamins C and E. *Clinics (Sao Paulo)*, 67(7):785-92.
- Ali, M.(1989). Studies on the prepubertal development of the reproductive organs and other related endocrine glands in male Nili Ravi buffalo bull calves of 6 months age. M.Sc. Thesis, Department of Animal

- Reproduction, College of Veterinary Science, Lahore-Pakistan.
- Andreussi ,P.A.T., Costa, D.S., Faria, F.J.C., Fernandes,C.A.C., Santos, M.D., and Silva, J.C.B. (2014).Testicular histomorphometric Evaluation of Zebu Bull Breeds. An internatio. J. Braz. Arch. Biol. Technol. 57 (6) pp 900-907.
- Aqeel, M.M.AL-Mahmodi., Waleed, J.AL-Kelaby., and Ali, A.J.AL- Ramahy. (2017). Testis Morphobiometrical studies of the adult Ram and Buck in AL-Najaf AL-Ashraf Province. Mirror of Research in Veterinary Sciences and Animals. 6 (3), 32-39.
- Aspinall ,V.O., and Reilly, M. (2005). Introduction to Veterinary Anatomy and Physiology. Butter Worth-Heine Mann PP 164-168.
- Ball, P.J.H., and Peters, A.R. (2004). Reproduction in Cattle. 3ed (ed). Black Well pp 13-15
- Brito,L.F.C.,Silva, A.E.D.F., Unanian, M.M., Dode, M.A.N., Barbosa, R.T., and Kastelic, J,P. (2004). Sexual development in early- and late-maturing Bos indicus and Bos indicus x Bos taurus crossbred bulls in Brazil. Theriogenology New York Elsevier Scie. Inc. 62(7) pp 1177–1217.
- Budras ,K.D., Sack, W.O., and Röck, S. (2009). Anatomy of the horse. 5th (ed.). Schlütersche Verlagsgesellschaft mbH and Co. KG. Hans-Böckler-Alle. pp 84-86.
- Dyce ,K.M., Sack W.O., and Wensing, C.J.G .(2010). Veterinary Anatomy. 4th (ed.): Saunders 3251 River port Lane st. Louis Missouri (63043) pp 124-129.
- El-Jack, A.H. (1980). The anatomy of the male genital system of the one humped camel. Zentralbl.Veterinärmed.C 9, 92 ff.
- Etim, N. A.(2015). Physiological Relationship between Scrotal Morphometric hypoprolactin aemia in the ram plasma gonadotrophin levels, LH and FSH receptors and histology of the testis. Reprod. Nutr. Develop (22) pp 621-630.
- Galmessa,U.,Terefe,F.,Abegaz,S.,Duguma,G., and Gizaw,S.(2000). Determination of the minimum body weight and its feeding requirement for early breeding in Horro ewe lambs. In Conference of Ethiopian Society of Animal Production, 8, Addis Abeba (Ethiopia), 24-26 Aug 2000. Ethiopian Society of Animal Production.
- Gitaindro ,N. A., Shah, M.A. R., Muhammad, N. I., Kazi ,M. I. M., Ismat, A. B., and Nayan, B. (2014). Morphological analysis of testes in pubertal bulls (Bos indicus) in Bangladesh. Journal of Chemical, Biological and Physical Sciences, Aug. 2014, Vol. 4, No. 4; 3318-3325.
- Hahn, J., Foote, R. H., and Seidel, G. E. Jr.(1969). Testicular growth and related sperm output in dairy bulls. *J. Anim. Sci.*, 29(1):41-7.
- Ibrahim, A.A., Aliyu, J., Ashiru, R.M., and Jamilu, M. (2012). Biometric Study of the Reproductive Organs of Three Breeds of Sheep in Nigeria. *Int. J. Morphol* 30(4) pp1597-1603.
- Karaman, M. I., Kaya, C., Caskurlu, T., Güney, S., and Ergenekon, E.(2005). Measurement of pediatric testicular volume with Prader orchidometer: comparison of different hands. *Pediatr. Surg. Int.*, 21(7):517-20.
- Mahmud, M. A., Onu, J, E., Shehu, S. A., Umaru, M. A., Danmaigoro A., and Bello ,A. (2015). Comparative Gross and Histological studies on testis of one-humped camel bull, UDA Ram and Red sokoto Buck. *Int. J. multidisciplinary research and inform. (IJMRI)* 1(1) pp 81-84.
- Mukasa- Mugerwa, E., Ephraim, B.T., and Adesse, T.(1986), Productivity of indigenous sheep and goats in the Ada district of the Ethiopian highlands.
- Ott, R. S.; Heath, E. H. & Bane, A. Abnormal spermatozoa, testicular degeneration, and varicocele in a ram. *Am. J. Vet. Res.*, 43(2):241- 5, 1982.
- Osinowo, O.A. (1990). Breed selection, reproduction and breed management in the local small ruminant breeds. In: The Nigerian sheep and Goat Production Manual. Osinowo, O.A. and A.A. Abatan (eds.) National Animal Production Research Institute (NAPRI) Workshop Training, Pp 7-18.
- Paltiel, H. J.,Diamond, D. A., Di Canzio, J.,Zurakowski, D., Borer, J. G., and Atala, A. (2002).Testicular volume: Comparison of orchidometer and us measurements in dogs. *Radiology*, 222(1):114-9.
- Purbey, L. N., and Choudhury, N.(1985). Biometry of different parts of morbid genitalia in nondescript male buffalos. *Indian Vet. Med. J.*, 9:12- 15.

- Raji ,A.O., Igwebuike, J,U., and Aliyu, J. (2008). Testicular Biometry and its Relationship with body weight of indigenous Goats in a semi arid region of Nigeria . (ARPN) J. of Agricultural and Biol. Scie Asian Research Publishing Network. 3(4) pp 6-9.
- Riviers ,D., and Williams,M.J.B. (1984). Testes development and production of spermatozoa in the cockerels (*Gallus domesticus*). *Reprod. Bio. of Poultry*. Longman, Harlow,. pp.183-202.
- Sakamoto, H., Saito, K., Oohta, M., Inoue, K., Ogawa, Y., and Yoshida, H.(2007). Testicular volume measurement: Comparison of ultrasonography, orchidometry and water displacement. *Urology*, 69 (1):152-7.
- Sakr, S., Shalaby, S. Y. Carbendazim.(2012).Induced testicular damage and oxidative stress in albino rats: Ameliorative effect of liquorice aqueous extract. *Toxicol. Ind. Health*, doi: 10.1177.
- Sarma, K., and Devi, J. (2012). Changes in the Seminiferous Epithelium of the Testes during Postnatal Development in Assam Goat. *Anat. Res. Int.* (2012) Article ID 620924.
- Silva, M. R., Pedrosa, V. B., Silva, J. C., Eler, J. P., Guimarães, J. D., and Albuquerque, L. G. (2011). Testicular traits as selection criteria for young Nellore bulls. *J. Anim. Sci.*, 89(7):2061-7.
- Skidmore, L.(2000). Anatomy of the camel reproductive tract. Recent advances in camelid reproduction. International Veterinary Information Service, Ithaca, New York, USA.
- Steel, R.G.D., and Torry, J.H. (1996). Principles and procedures of statistics. A Biometrical Approach. 3ed (ed): New York McGraw-Hill Book Co. Inc pp 672.
- WGemeda, A.E., and Workalemahu, K. (2017). Body Weight and Scrotal-Testicular Biometry in Three Indigenous Breeds of Bucks in Arid and Semiarid Agroecologies, Ethiopia. *J. Vet. Med.* 2017: 5276106.