

DUHOK TECHNIQUE; A NEW MODIFICATION OF THE HYPOSPADIAS SURGERY TECHNIQUE TO PREVENT INADVERTENT CATHETER REMOVAL AFTER SURGERY

SHAKIR SALEEM JABALI, QADIR M. SALIH*, AVEEN MUNIB MAHMOUD** and AYAD AHMAD MOHAMMED*

*Dept. of Surgery College of Medicine, University of Duhok, Kurdistan Region-Iraq

**Dept. of Clinical pharmacy. College of Pharmacy, University of Duhok, Kurdistan Region-Iraq

(Received: November 14, 2022; Accepted for Publication: April 6, 2023)

ABSTRACT

Introduction: The results of hypospadias surgery had improved greatly over the last decades and the surgical techniques are still evolving. One of the most important steps in the success of surgery is the urinary diversion. Updated guidelines recommend the use of an appropriate sized silastic catheter just inside the bladder and for limited duration to improve the results.

Material and methods: This cross section study involved 71 consecutive patients who underwent hypospadias surgery from January, 2018 to August 2020. The external part of urethral catheter was incised into wings which were anchored to the glans circumferentially to prevent stent displacement, we incised the catheter into 4 wings in most patients. None of the wings should be placed over the suture line at the glans to prevent pressure necrosis and wound disruption. The aim of study is to present our new modification in catheter fixation technique in hypospadias surgery to prevent inadvertent catheter removal postoperatively.

Discussion: Most of the patients had no complications (85.92%). The commonest reported complications were meatal stenosis and fistula, and other complications were rare. No catheter related complications were reported.

Conclusions: Repositioning of the catheter after inadvertent removal may result in anastomotic disruption or fistula. The catheter should be inserted inside the bladder rather than making it a urethral stent. Advantages of our technique were a steadier catheter, the catheter is made as short as possible which decrease the chance of blockage, more easily handled catheter as napkin can be applied easily, and easier removal of catheter.

KEYWORDS: Hypospadias, urinary catheter, inadvertent catheter removal, hypospadias complications, catheter complications, meatal stenosis.

INTRODUCTION

Hypospadias is defined as an incomplete virilization of the genital tubercle that result in an ectopic urethral opening on the ventral aspect of the penis anywhere from the glans penis to the perineum with or without a ventral curvature and a ventral pre-pucial defect. Successful hypospadias surgery is defined as achieving a straight penis at erection and an external meatus near the tip that permits normal voiding in standing position, normal sexual intercourse, and a satisfactory cosmetic appearance. Myriads of surgical techniques and practice regarding hypospadias surgery are described and still the scope of hypospadias surgery is under evolution [1-5].

Hypospadias is classified according to the location of the meatus into 3 types: anterior hypospadias which account for around 50% of the cases, in this type the meatus is located in the glans or in the subcoronal region, middle hypospadias which constitutes around 30% of the cases, in this type the meatus is located in shaft of the penis, and the posterior hypospadias which constitutes around 20% of the cases, in this type the meatus is present in the penoscrotal junction, the scrotum, or the perineum [6].

Hypospadias may be associated with some other congenital malformations including anomalies of the upper or the lower urinary tract, the presence of associated anomalies increase the severity of hypospadias [6].

The results of hypospadias surgery had improved greatly over the last decades and the

techniques for repairs are still evolving. The ideal surgical repair for the proximal hypospadias is the two staged repair. Numerous techniques are currently performed to correct the associated chordee [6, 7].

Before surgery evaluation is required including ultrasonography, endoscopy which will visualize the prostatic utricle thus avoiding problems during catheterization, micturating cystourethrogram, and sometimes karyotyping in severe cases when the genitalia is ambiguous, this will also exclude intersex anomalies. Detailed preoperative assessment will help to decide the plan for surgery, sometimes the plan of surgery is changed at table during surgery according to the case [6, 8].

The main points that will determine the success of hypospadias surgery are; the timing of surgery, best results are achieved when surgery is done between 6-18 months, meticulous dissection and approximation of tissues, the use of magnification loops, microsurgical instruments, the use of appropriate suture material, minimum and a pin point use of electrocautery, tension free repair, maintaining the vascularity of all the layers, and a single staged repair whenever possible and epithelial inversion. Some of the patients may require a staged procedure. Hormonal therapy is sometimes required for patients with small size penis or those with repeated surgery. This may be given systemically or locally, although there is no general agreement about their usage [6, 9].

One of the most important steps in the success of surgery is the urinary diversion, there still a great debate whether the rate of complication is higher in those stented or the non-stented repairs. The rate may be increases in patients who developed urinary retention and require catheterization after that. Update guidelines recommend the use of an appropriate sized silastic catheter just inside the bladder and for limited duration for example one week have been shown to improve the results. The most important points that require special attention after surgery are; catheter care, appropriate dressing, antibiotics and analgesics [6].

There are numerous types of surgeries for hypospadias, and the technique of surgery is demanding and require great experience, it is recommended that the surgery must be done by a surgeon who can master at least 6 techniques and have a work experience of around 50 cases under supervision of a senior surgeon. [3, 6]

Hormonal therapy is indicated in a group of selected patients such as those with very small sized penis or those with repeated surgeries. Systemic β -HCG, testosterone, or dihydrotestosterone may sometimes be used. Local testosterone creams are sometimes used, the use of hormonal stimulation therapy aimed to increase the penile length significantly, enhance both the vascularity and the thickness of corpus spongiosum, and may reduce the severity of hypospadias. [6]

The presence of more than 250 techniques for hypospadias repair indicate the lack of uniformity of the complication rates. There is a great number of possible complication that occur after hypospadias surgery, such as bleeding, hematoma, fistula, meatal stenosis, infection, dehiscence of the wound, flap necrosis, urethral stricture, diverticulum of the urethra, persistence of the penile curvature, hairy urethra with stone formation, bladder spasms, penile torsion, unfavorable cosmetic outcome, together with other functional, sexual, and psychological problems. Inadvertent stent displacement is regarded one of the acute complications. The use of late absorbable suture materials is appropriate, polyglactin suture material or PDS are appropriate for closure of the innermost layer with epithelial inversion, while polyglyconate suture material can used for other layers. [1, 4-6, 10, 11]

The urinary catheter should be inserted inside the bladder rather than making it as a urethral stent. Numerous catheter related problems have been reported such as blocking of the catheter, kinking, inadvertent catheter removal, and catheter knot. Blockage may be due to blood clot or dehydration, this problem can be managed by irrigation with sterile saline. Repositioning of the catheter after inadvertent removal may result in anastomotic disruption, authors recommend that inadvertent removal of the catheter within the first 48 hours is best managed with the insertion of supra-pubic catheter, inadvertent removal is found to be one of the most important causes for the development of meatal stenosis and fistula development. Knotting of the catheter is very rare and may occur in cases when a too long catheter is inserted which result in intra-vesical coiling [5, 9].

The aim of study is to present our new modification in catheter fixation technique in hypospadias surgery to prevent inadvertent catheter removal postoperatively.

Patients and methods:

Registration: In accordance to the World Medical Association's Declaration of Helsinki 2013, the work of this article is registered in the Research Registry, and the unique identifying number is: researchregistry **6497**.

The link to the registration page is: <https://www.researchregistry.com/browse-the-registry#home/registrationdetails/60124eb810b52a001c90418f/>

Study design: This is a cross sectional study which involved 71 consecutive patients who underwent surgery for hypospadias from the period from January, 2018 to August 2020. The operations were performed by 2 surgeons who are specialized in the field of pediatric surgery and urosurgery. Patients then followed for at least 1 year after surgery to for any possible complications related to surgery.

Before surgery, detailed examination is mandatory which include estimation of the size of the penis, shape of the glans, site of the meatus, the development of the urethral plate, the length of the hypoplastic urethra, the presence or absence of chordee and its severity,

the dorsal hood, the scrotal and testicular development, and any other associated congenital anomalies. Occasionally probing may be done to exclude the possibility of duplication of the urethra.

All surgeries were performed under general anesthesia, patients received a dose of 2nd generation cephalosporin group at induction of anesthesia. A stay suture is fixed to the tip of the glans penis which was used for traction, then the urethral plate was incised from the tip of the glans at the site of the future external meatus down to a suitable length. The urethra was then sutured over 8 Fch catheter using 6/0 PDS suture material, the second layer of subcutaneous tissue was then sutured using 6/0 PDS suture material. Then the glans was sutured over the urethra using 6/0 polyglactin in a subcuticular manner. Associated malformations such as chordee, hernias, hydrocele, or undescended testis were dealt with accordingly. The modification is in the urethral catheter which was incised into 2, 3, or 4 wings, each of them was anchored to the skin circumferentially to prevent movement of the stent which is the main point that determine the success of the operation. (Figures 1-9).

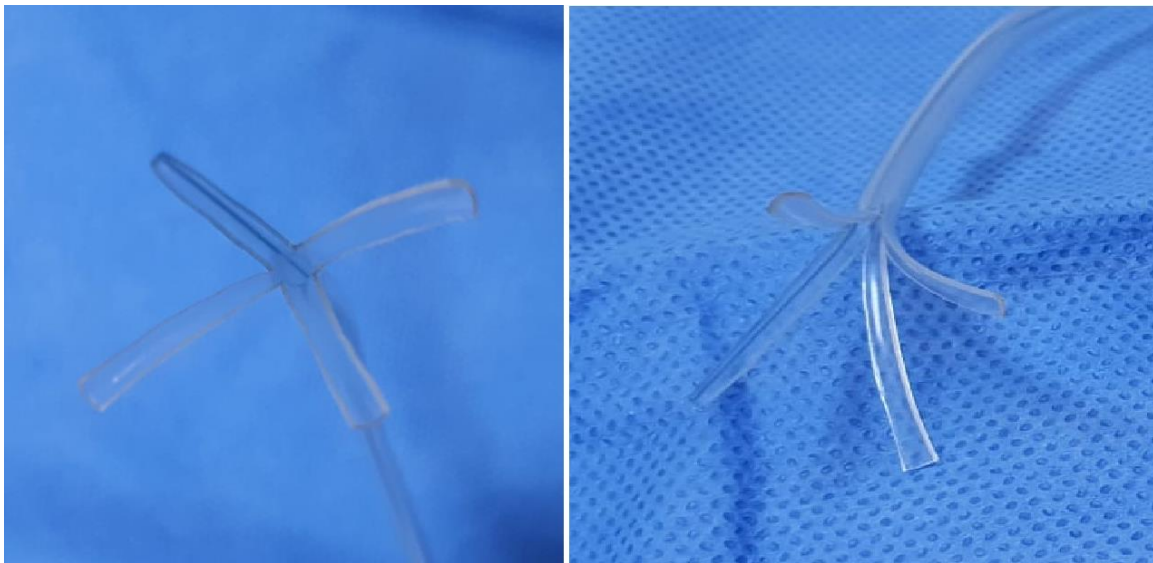


Fig. (1): A picture showing the tip of the catheter after being divided into 4 wings.

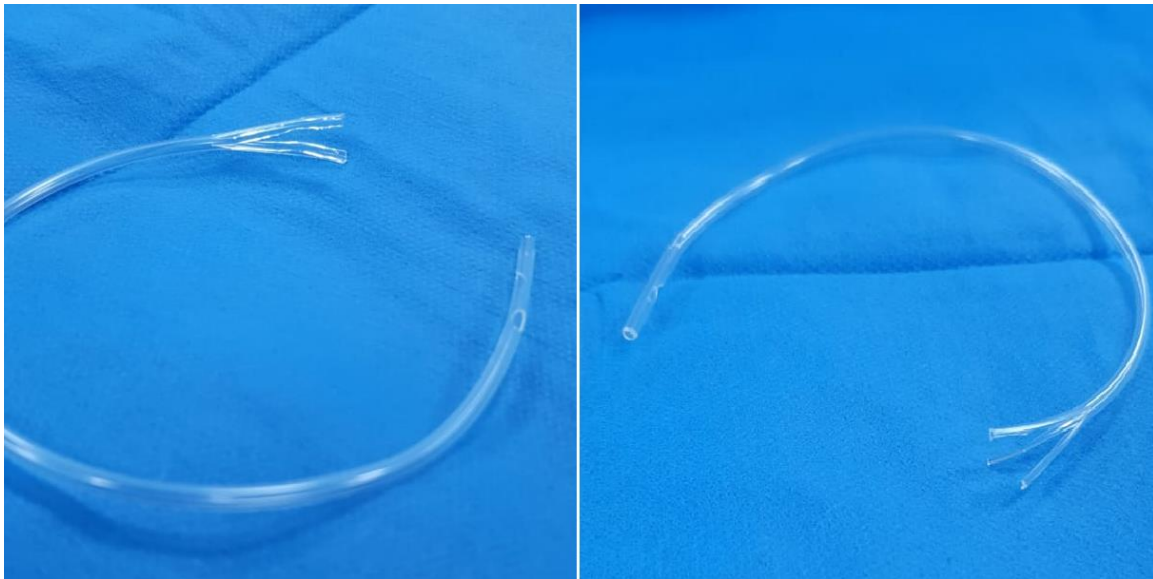


Fig. (2): A picture showing the tip of the catheter after being divided into 2 or 3 wings.

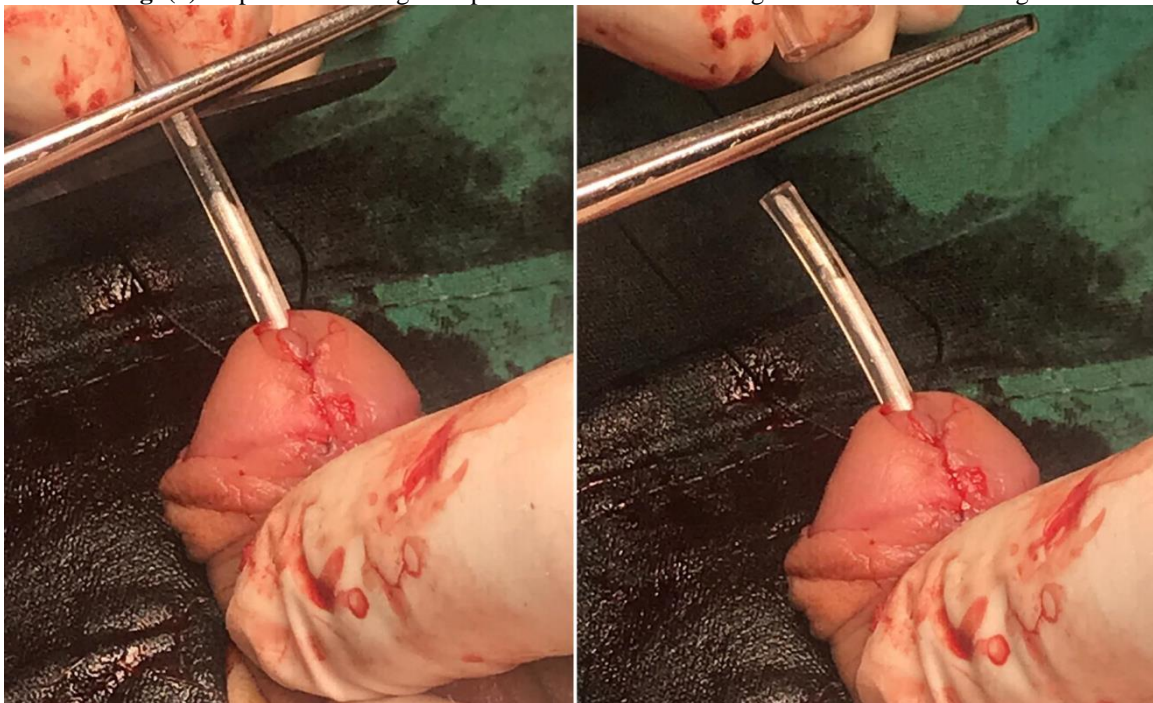


Figure (3): An intraoperative picture showing cutting of the urinary catheter to an appropriate distance from the meatus.

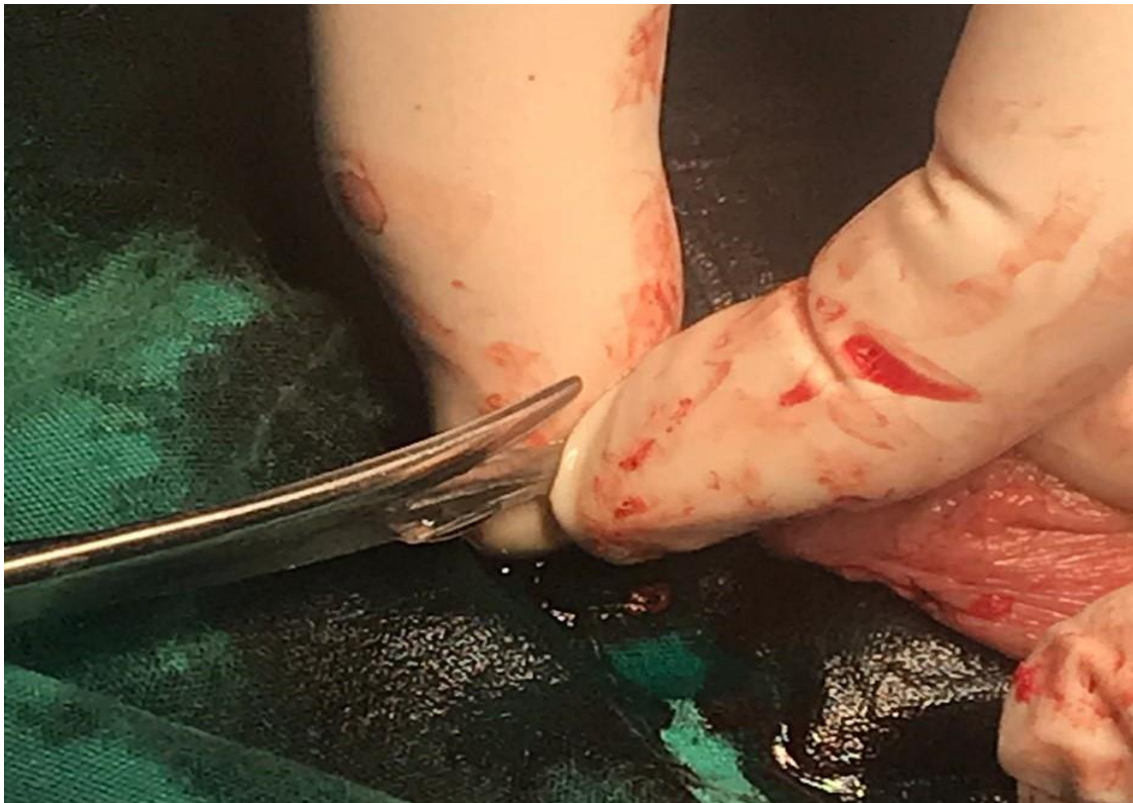

Fig. (4): An intraoperative picture showing cutting of the outside part of the catheter to 3 or 4 wings which will be then fixed to the glans.

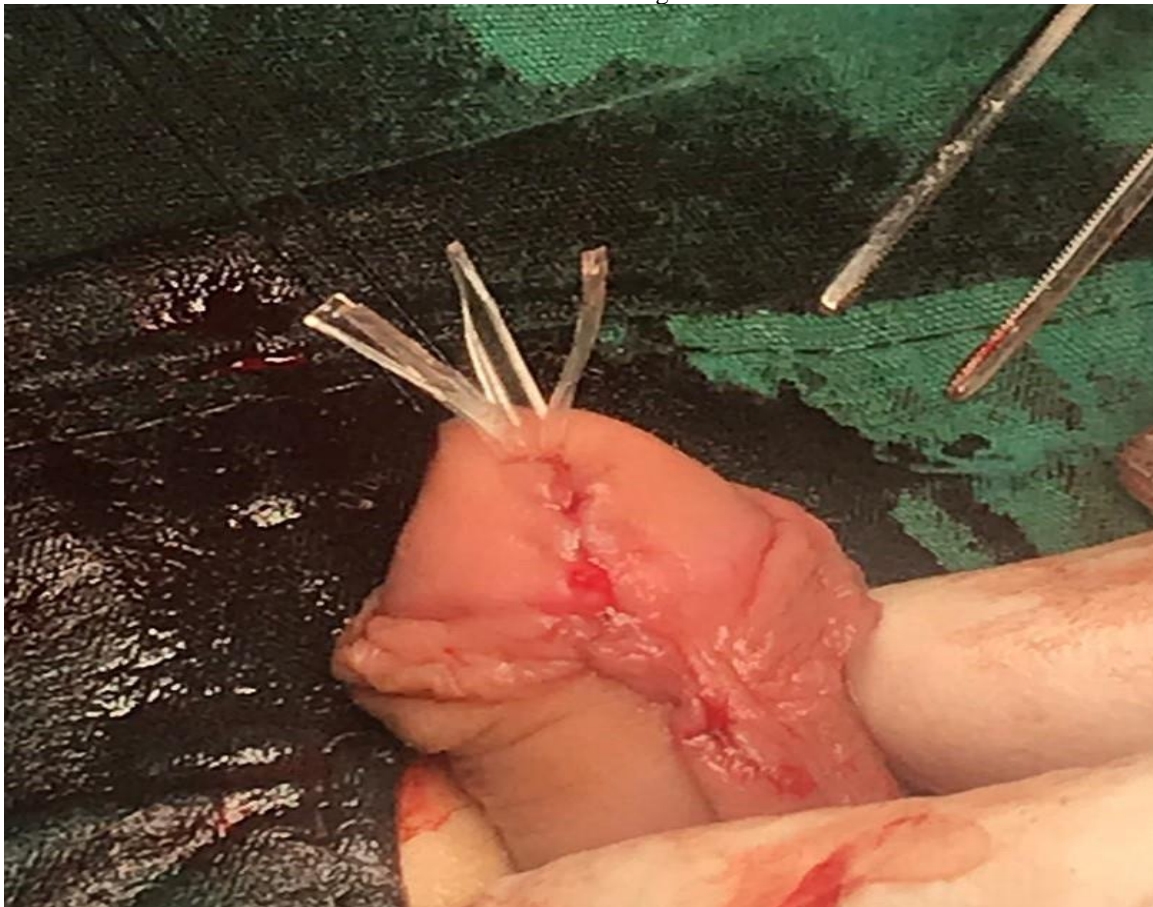


Fig. (5): An intraoperative picture showing the outside part of the catheter after being divided into 3 or 4 wings which will be then fixed to the glans.

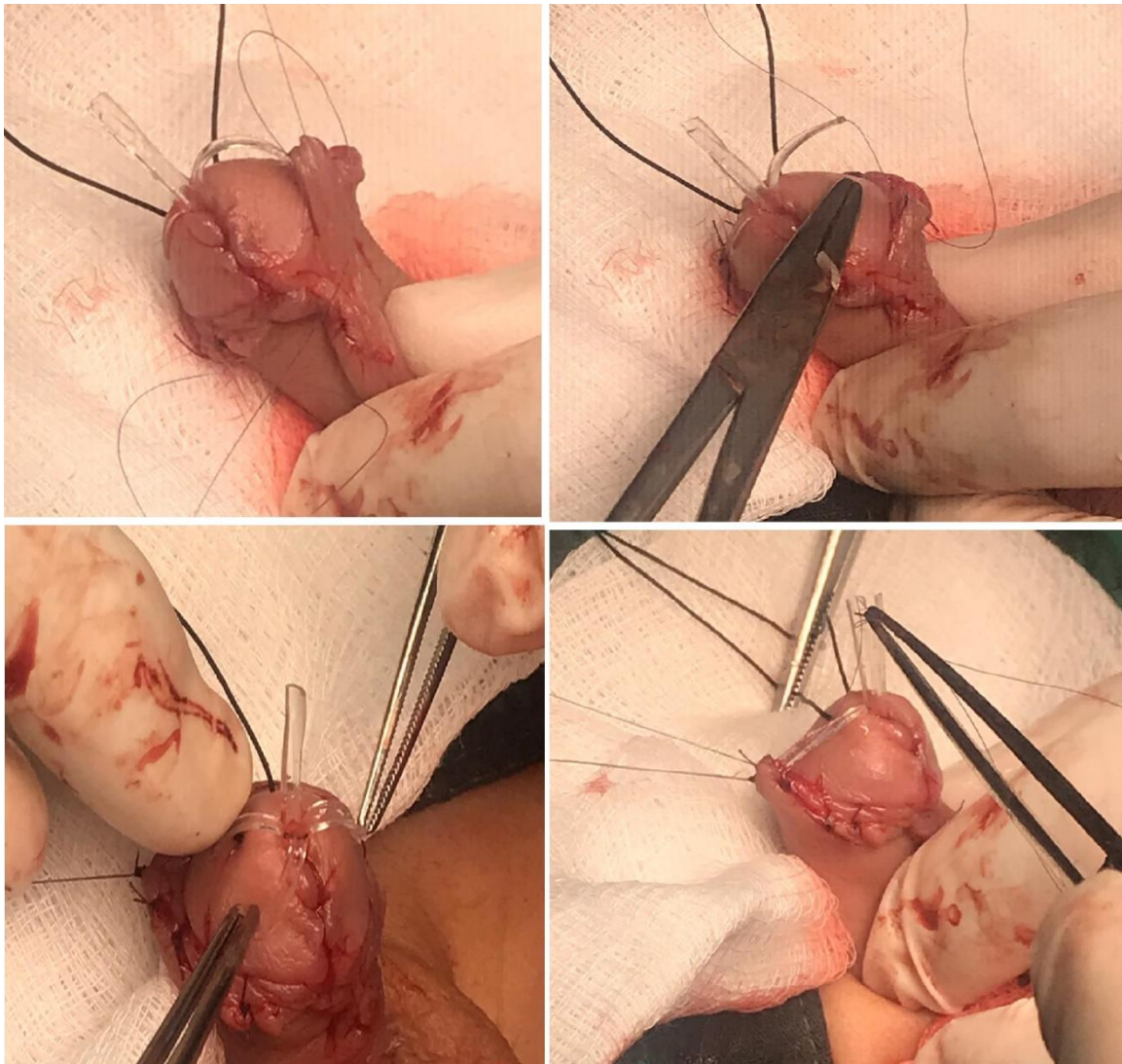


Fig. (6): An intraoperative picture showing the fixation of each wing of the catheter to the glans.

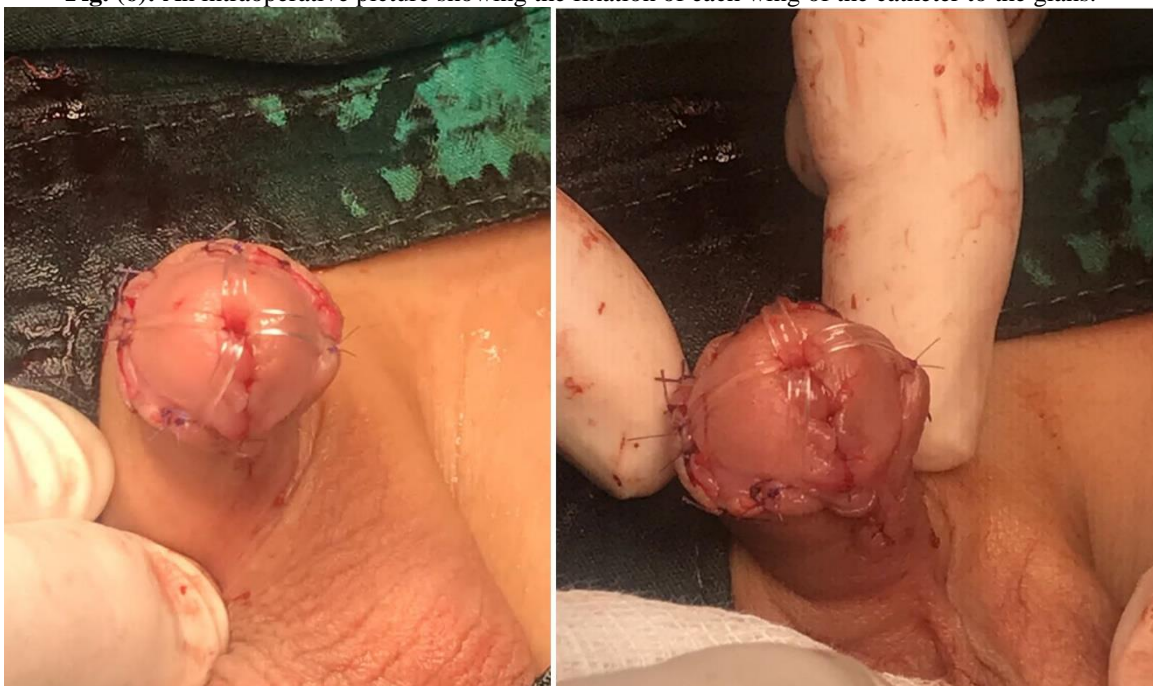

Fig. (7): An intraoperative picture showing the fixation of each of the 4 wings of the catheter to the glans.

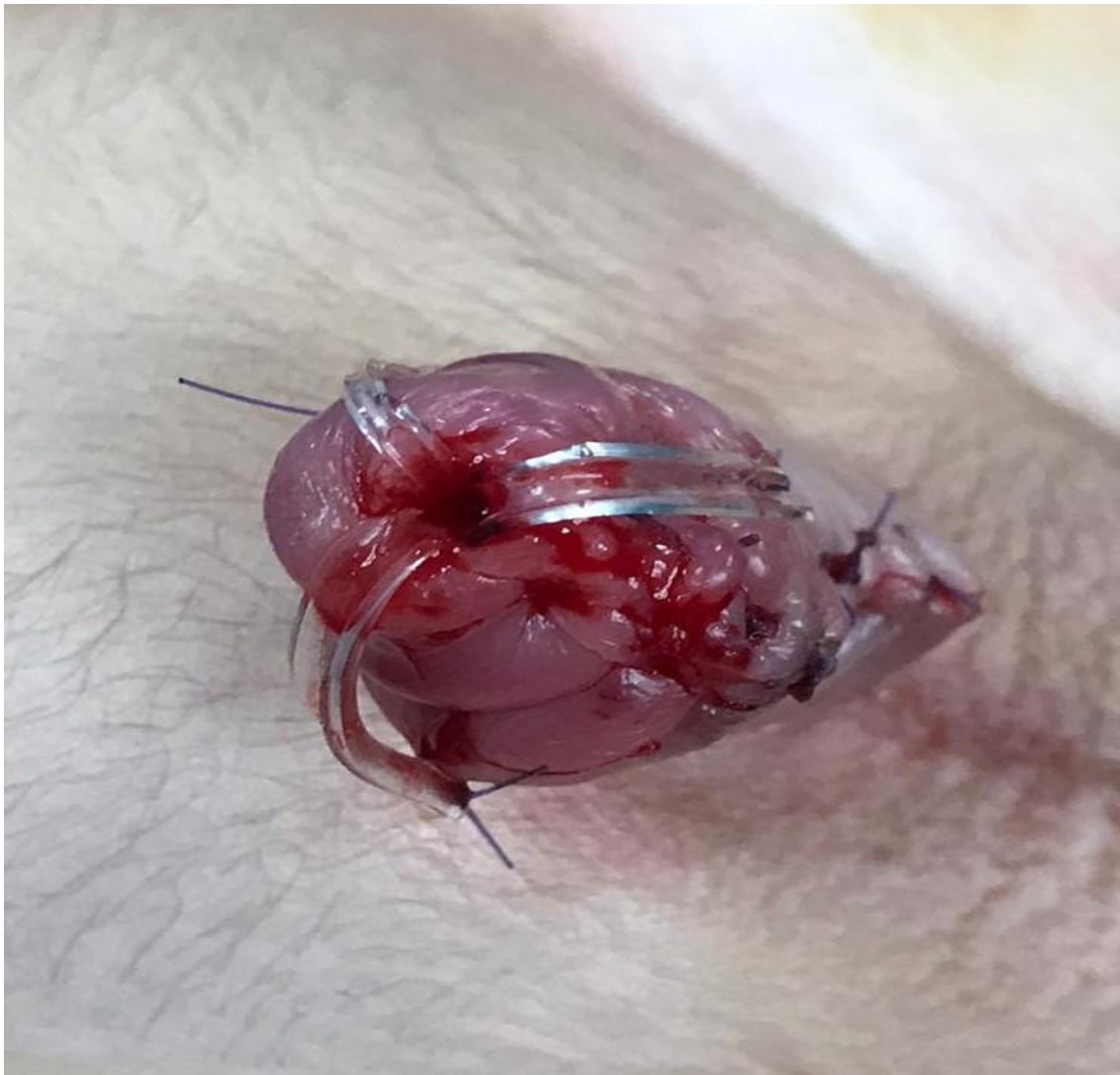

Fig. (8): An intraoperative picture showing the fixation of each of the 3 wings of the catheter to the glans which can be divided into 3 wings too.

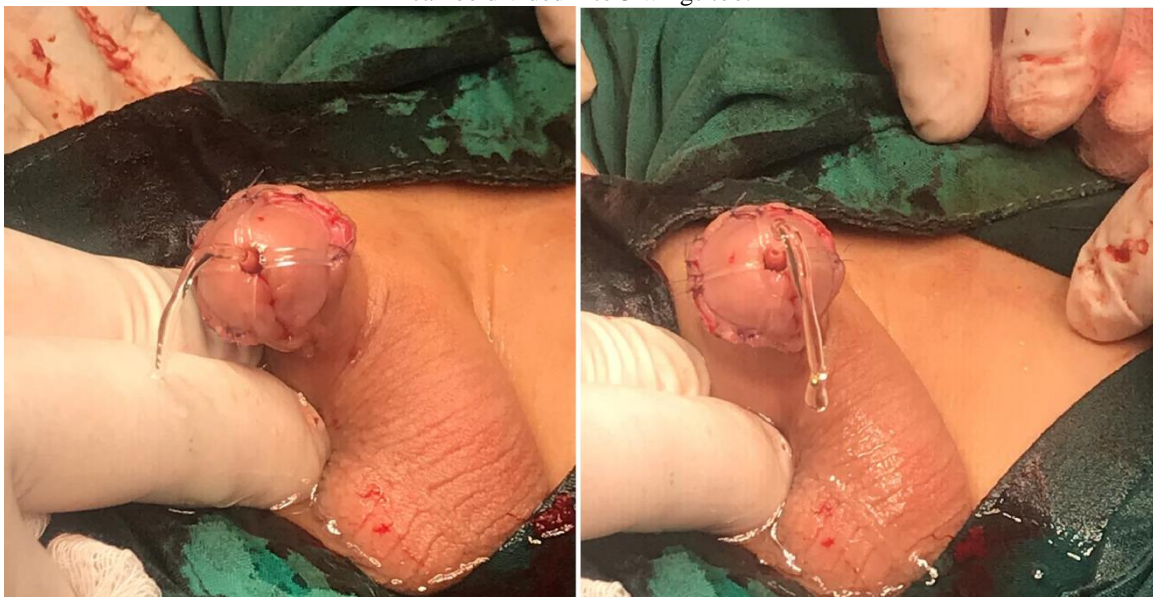

Fig. (9): An intraoperative picture showing the free streaming of the urine from the catheter after fixation of the wings of the catheter to the glans.

The dressings were removed on the 5th postoperative period and the catheter was removed on the 8th postoperative day.

The work of this article has been reported in line with the PROCESS criteria [12].

RESULTS

In most patients no associated anomalies were reported, however some patients had associated chordee, hernia, hydrocele, and undescended testis (Figure 10).

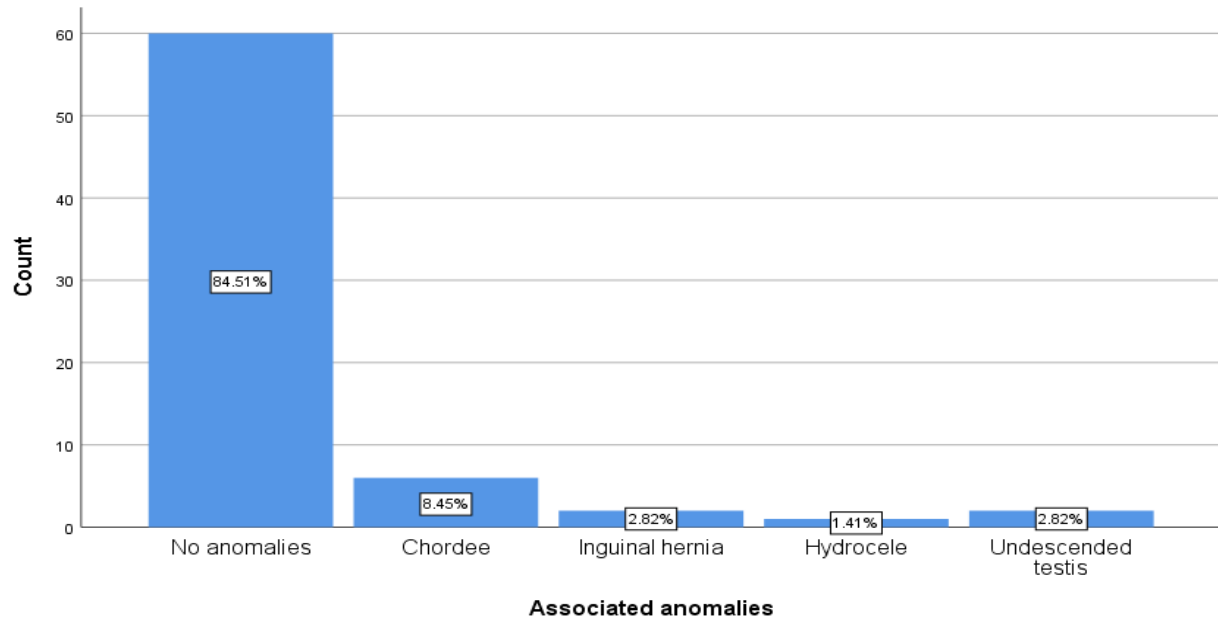


Fig. (10): A simple bar chart showing the rate of the associated anomalies.

In the majority of patients, no complications were reported (85.92%), the complication rate was 14.08%. (Figure 11).

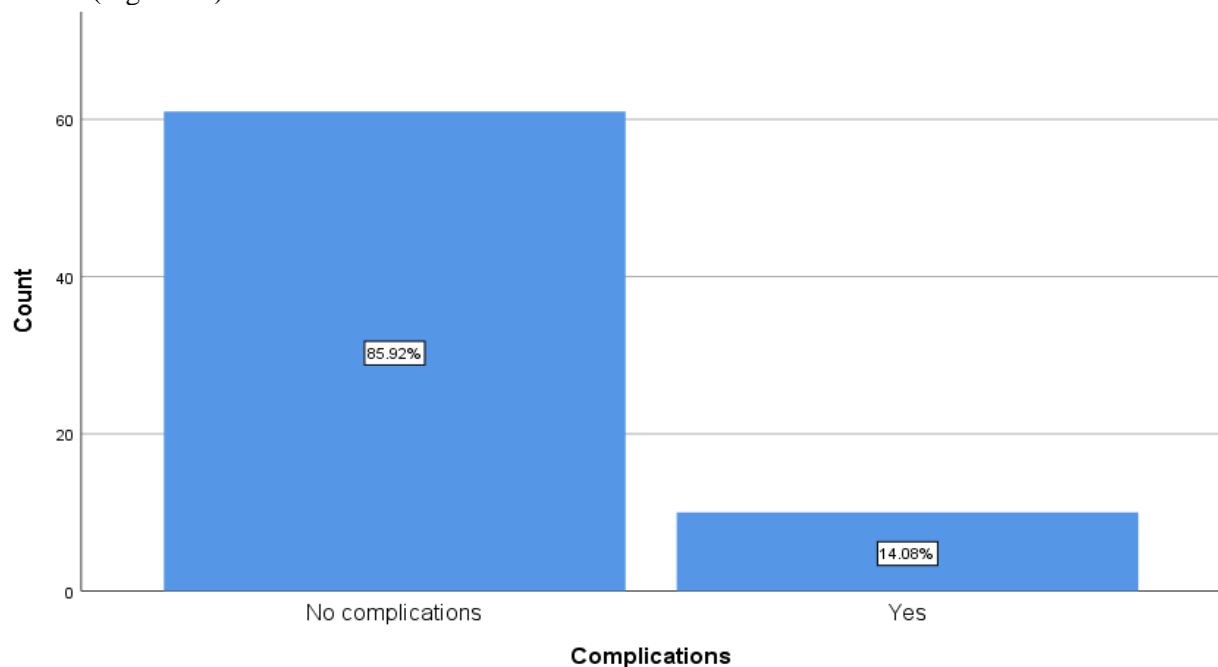


Fig. (11): A simple bar chart showing the rate of the complications among our patients.

Meatal stenosis and fistula were the most common reported complications. No any catheter related complications were reported among our patients. (Table 1).

Table (1): Showing the types of the complications among our patients.

Type of complication	Frequency	Percent
No complications	61	85.92
Meatal stenosis	4	5.6
Fistula	4	5.6
Infection	1	1.4
Infection + Partial wound disruption	1	1.4
Catheter related complications	0	0

DISCUSSION

There are numerous types of surgeries for hypospadias, and the technique of surgery is demanding and require great experience, it is recommended that the surgery must be done by a surgeon who can master at least 6 techniques and has a work experience of around 50 cases under supervision of a senior surgeon [3, 6].

Before surgery, detailed examination is mandatory which include estimation of the size of the penis, shape of the glans, site of the meatus, the development of the urethral plate, the length of the hypoplastic urethra, the presence or absence of chordee and its severity, the dorsal hood, the scrotal and testicular development, and any other associated congenital anomalies. Occasionally probing may be done to exclude the possibility of duplication of the urethra. The rate of associated other anomalies among our patients was 15.49%, they included inguinal hernia, undescended testis, and hydrocele. Chordee was reported in 8.45% of our patients which was corrected during surgery [6, 13, 14].

It is recommended by many authors that the best age for performing surgery is between 6-18 months, there is a great reduction in the level of anxiety when surgery is performed before 18 months, although some author found that there is no increase rate of complications when surgery is performed between 2-11 months [4, 15].

Hormonal therapy is indicated in a group of selected patients such as those with very small sized penis or those with repeated surgeries. Systemic β -HCG, testosterone, or dihydrotestosterone may sometimes be used. Local testosterone creams are sometimes used, the use of hormonal stimulation therapy aimed to increase the penile length significantly, enhance both the vascularity and the thickness of corpus spongiosum, and may reduce the severity of hypospadias [6].

The presence of more than 250 techniques for hypospadias repair indicate the lack of uniformity of the complication rates. There is a great number of possible complications that occur after hypospadias surgery, such as bleeding, hematoma, fistula, meatal stenosis, infection, dehiscence of the wound, flap necrosis, urethral stricture, diverticulum of the urethra, persistence of the penile curvature, hairy urethra with stone formation, bladder spasms, penile torsion, unfavorable cosmetic outcome, together with other functional, sexual, and psychological problems. Inadvertent stent displacement is regarded as one of the acute complications. The use of late absorbable suture materials is appropriate, polyglactin suture material or PDS are appropriate for closure of the innermost layer with epithelial inversion, while polyglyconate suture material can be used for other layers [1, 4-6, 10, 11].

The rate of the reported complications in our patients were 4.08% (10 patients) which is regarded as an acceptable rate when compared to the published data. The rate of complications varies and depend on many factors such as the severity of hypospadias, the age of patient, the technique of surgery, and the experience of the surgeon. Better results will be achieved when the surgical team adhere to the principles of both plastic and microsurgery, with a meticulous preoperative plan, and judicious care in the postoperative period [5, 16, 17].

Urethra-cutaneous fistula is the most common reported complication after hypospadias surgery and varies from 5-40% of the cases. This depend on the type of hypospadias and the technique of closure, higher rates are reported in posterior hypospadias when compared to the anterior type. The use of subcuticular suturing has significantly reduced the fistula rate (around 5%), when compared to other suturing techniques like the full thickness suturing (up to 16%), in our cases the rate of fistula occurrence was 5.6% (4 patients). This rate is not higher than world published data.

Second layer coverage have been shown to greatly reduce the rate of fistula occurrence [6, 18-20].

The rate of meatal stenosis among our patients was 5.6% (4 patients). The cause of meatal stenosis is usually technical. This complication is best avoided by generous incision of the ventral and the lateral sides of the glans at the site of the proposed neo-urethra, together with an adequate development of the tissue planes between the tips of the corpora and tissue of the glans penis [4].

Mild infection was reported in 1.4% of our patients (1 patient), and was reported in another patient (1.4%) in association with partial wound disruption. The incidence of infection is reported to occur in up to 30% of patients. Preoperative antibiotics and local application of antibiotics greatly reduce the infection rate. Wound dehiscence is a rare complication and in most cases it is due to compromise of the blood supply, tension applied during surgery, or vigorous removal of the dressing [5].

No catheter related complications were reported among our patients. During surgery, surgeons must follow certain points when they insert the catheter during, at start and once the tube is inserted inside the bladder, a slow catheter withdrawal should be performed until there is no dribbling of urine indicating that the tip of the catheter is located just distal to the internal sphincter, then the tube should be passed inside again slowly until the urine reappear a gain indicating that the tip of the catheter is just proximal to the internal sphincter, lastly the catheter should be pushed inside for further 2-3 cm and then anchored at this position using the traction suture at the glans penis. Following these points will greatly reduce the catheter related complications. In our study we modified the technique of catheter anchoring in order to prevent inadvertent removal of the catheter, the same steps of the insertion were followed then the tip of the catheter was divided into 3 or 4 wings which were then fixed to the skin, this technique secured the stent and prevented inadvertent catheter removal in any of our patients. One of the very important points in this technique is that none of the wings should be placed over the suture line at the glans penis to prevent pressure necrosis and wound disruption [5].

Follow up is recommended after surgery and also in the adult life, this should include any possible complications, cosmetic appearance of

penis, functional outcome regarding micturition and sexuality, and the quality of life in general and psychosexual life. In our study most patients had no complications, however the commonest complication in our study was meatal stenosis and fistula in 5.6% for each of them, infection also was reported in 1.4%, and infection with wound disruption in 1.4%. a study that was done by JB Myers et al they showed that stricture was the commonest complication, followed by fistula and persistent hypospadias [1, 21].

CONCLUSIONS

The catheter should be inserted inside the bladder rather than making it a urethral stent. Repositioning of the catheter after inadvertent removal may result in anastomotic disruption or fistula. Advantages of our technique were a steadier catheter, the catheter is made as short as possible which decrease the chance of blockage, more easily handled catheter as napkin can be applied easily, and easier removal of catheter. Further studies are required to include larger number of patients with an extended periods of follow up to evaluate this technique more.

RECOMMENDATIONS

Further studies are required to include larger number of patients with an extended periods of follow up to evaluate this technique more.

Informed consent: an informed written consent was obtained from the parents before the conduction of this study.

Conflicts of interest: The authors declare that there is no conflict of interest.

Sources of funding: The authors are the source of funding.

REFERENCES

- Springer, A., *Assessment of outcome in hypospadias surgery—a review*. *Frontiers in pediatrics*, 2014. **2**: p. 2.
- Steven, L., et al., *Current practice in paediatric hypospadias surgery; a specialist survey*. *Journal of pediatric urology*, 2013. **9**(6): p. 1126-1130.
- Springer, A., S. Tekgul, and R. Subramaniam, *An update of current practice in hypospadias surgery*. *European Urology Supplements*, 2017. **16**(1): p. 8-15.
- Hayashi, Y. and Y. Kojima, *Current concepts in hypospadias surgery*. *International journal of urology*, 2008. **15**(8): p. 651-664.

- Bhat, A. and A.K. Mandal, *Acute postoperative complications of hypospadias repair*. Indian journal of urology: IJU: journal of the Urological Society of India, 2008. **24**(2): p. 241.
- Bhat, A., *General considerations in hypospadias surgery*. Indian Journal of Urology: IJU: Journal of the Urological Society of India, 2008. **24**(2): p. 188.
- Springer, A., W. Krois, and E. Horcher, *Trends in hypospadias surgery: results of a worldwide survey*. European urology, 2011. **60**(6): p. 1184-1189.
- Qadir, Q.M.S. and A.A. Mohammed, *Congenital pouch colon in Duhok, outcome and complications: Case series*. Annals of Medicine and Surgery, 2019. **45**: p. 86-90.
- Cimador, M., M. Castagnetti, and E. De Grazia, *Urethrocutaneous fistula repair after hypospadias surgery*. BJU international, 2003. **92**(6): p. 621-623.
- Sadeeq, K.J., R.T. Yaqo, and A.A. Mohammed, *Inflammatory pseudotumor of the tunica albuginea and the tunica vaginalis: case-report*. Urology case reports, 2019. **26**.
- Aldohuky, W. and A.A. Mohammed, *Scrotal abscess as a manifestation of posterior duodenal perforation; a very rare presentation*. Urology case reports, 2019. **27**: p. 101010.
- Agha, R.A., et al., *The PROCESS 2020 guideline: updating consensus Preferred Reporting of CasE series in surgery (PROCESS) guidelines*. International Journal of Surgery, 2020.
- Jabali, S.S. and A.A. Mohammed, *Crossed testicular ectopia: Case report with review of literature*. International Journal of Surgery Case Reports, 2020. **75**: p. 189-192.
- Jabali, S.S. and A.A. Mohammed, *Triphallia (triple penis), the first reported case in human*. International Journal of Surgery Case Reports, 2020. **77**: p. 198-200.
- Belman, A.B. and E.J. Kass, *Hypospadias repair in children less than 1 year old*. The Journal of urology, 1982. **128**(6): p. 1273-1274.
- Hansson, E., et al., *Analysis of complications after repair of hypospadias*. Scandinavian journal of plastic and reconstructive surgery and hand surgery, 2007. **41**(3): p. 120-124.
- Appeadu-Mensah, W., et al., *Complications of hypospadias surgery: Experience in a tertiary hospital of a developing country*. African journal of paediatric surgery: AJPS, 2015. **12**(4): p. 211.
- Aigrain, Y., et al., *Hypospadias: surgery and complications*. Hormone research in paediatrics, 2010. **74**(3): p. 218-222.
- Dhua, A.K., et al., *Soft tissue covers in hypospadias surgery: is tunica vaginalis better than dartos flap?* Journal of Indian Association of Pediatric Surgeons, 2012. **17**(1): p. 16.
- Jabali, S.S. and A.A. Mohammed, *Dorsal urethrocutaneous fistula caused by an impacted stone at the bulbar urethra: case report*. International Journal of Surgery Case Reports, 2021.
- Myers, J.B., et al., *Treatment of adults with complications from previous hypospadias surgery*. The Journal of urology, 2012. **188**(2): p. 459-463.

ته کنیکا دهۆک راستفه کرنه کا نوی بو ته کنیکا نشته رگه ریا لوله یا ژیری بو نه هیلانا راکرنا قهسته را بیدهستی
پشتی نشته رگه ری

پوخته

پیشه کی: ددهه سالین بوریدا نه نجامین نشته رگه ریا لوله یا ژیری ب شیوه کی مه زن دباشوون و هیشتا
ته کنیکین نشته رگه ری به رهف پیشه چوونئ یه، ژ گرتترین پینگا قین سه رکه فتنا نشته رگه ری گوهورینا
ریره وی میزیه، شیره تین نوی ناموژگاری د دهت بو بکارئینانا قهسته را سیلیستیکی یا قه باره گونجای
دناف میزدانی بتنیدا بو دهمه کی دهست نیشانکی بو باشکرنا نه نجامان.

کهرهسته و ریک: نه فی قه کولینا پارچه یی یان پان (71) نه خووش لدویف ئیک بخووه گرت و که فتنه بهر
نشته رگه ریا لوله یا ژیری ژ هه یفا کانوونا دووی 2018 هه تا هه یفا ته باخی 2020، به شی دهره ژ قهسته را
لوله یی هاته شه فکرن ل بهشین بنه جهکری د سه رکیدا ب شیوه کی دهووربه ر کو پالپشت ژ جه نه چیت،
نم رابووین ب پارچه کرنا قهسته ری و دهمی نه خووشاندا مه کره (4) بهش، ناپیت ژ چ بهشان ل سه ره یلا
دورینی دسه رکیدا بهیته دانان، دا پهستان پویج نه بیت و برین تیک نه چیت.

نارمانج ژ قه کولینئ نه وه کو راستفه کرنا خو یا نوی دته کنیکا بنه جهکرنا قهسته ری د نشته رگه ریا لوله یا
ژیری پیشکیش بکه یین بو نه هیلانا راکرنا قهسته را بیدهستی پشتی نشته رگه ری.

گینگه شه: هه می نه خووشان دووژانگ لک نه بوون (85.92%) دووژانگا پتر به لاقه کو هاتیه راگه هاندن
ته نگبوونا گوشتی و ناسوری بوو. دووژانگین دی دکیمبوون و چ دووژانگین په یوه نیدار ب قهسته ریقه
نه هاتنه راگه هاندن.

دهرئه نجام: چیدبیت گوهورینا جهی قهسته ری پشتی راکرنا بیدهستی بته نه گه ری تیکچوونا قه بوونئ یان
ناسوری، دقیت قهسته ر بچته دناف میزدانی، شوینا وی چندی کو بته پالپشته ک بو ریروه و میزی،
تایبه تمه ندین ته کنیکا مه قهسته ره کا پتر نه جهوو، و ب کیمترین دم قهسته ره هاته چیکرن، نه قه دهلیفا
گرتنی کیم دکهت، و چیدبیت ب ساناهی سه ره ده ری دگه ل قهسته ری بهیته کرن، کو چیدبیت ب ساناهی
دستمال بهیته بکارهینان و ب ساناهی قهسته ره بهیته راکرن.

په یقین کللی: ریروه و میزی یا ژیری، قهسته را میزکرنی، راکرنا بیدهستی یا قهسته ری، دووژانگین ریروه و میزی
یا ژیری، دووژانگین قهسته ری، ته نگبوونا گوشتی.

تقنية دهوك تعديل جديد لتقنية جراحة الإحليل التحتي لمنع إزالة القسطرة غير المقصودة بعد الجراحة

الخلاصة

مقدمة: تحسنت نتائج جراحة الإحليل التحتي بشكل كبير خلال العقود الماضية ولا تزال التقنيات الجراحية تتطور. من أهم خطوات نجاح الجراحة تحويل مجرى البول. توصي الإرشادات المحدثة باستخدام قسطرة سيلستيكية ذات حجم مناسب داخل المثانة فقط ولمدة محدودة لتحسين النتائج.

المواد والطرق: تضمنت دراسة المقطع العرضي هذه 71 مريضاً متتاليًا خضعوا لجراحة الإحليل التحتي من يناير 2018 إلى أغسطس 2020. تم شق الجزء الخارجي من قسطرة الإحليل في أجنحة مثبتة في الحشفة بشكل محيطي لمنع إزاحة الدعامة ، وقمنا بتقطيع القسطرة إلى 4 أجنحة في معظم المرضى. لا ينبغي وضع أي من الأجنحة فوق خط الخياطة في الحشفة لمنع نخر الضغط واضطراب الجرح. الهدف من الدراسة هو تقديم تعديلنا الجديد في تقنية تثبيت القسطرة في جراحة الإحليل التحتي لمنع إزالة القسطرة غير المقصودة بعد الجراحة.

المناقشة: معظم المرضى ليس لديهم مضاعفات (85.92%). كانت المضاعفات الأكثر شيوعًا التي تم الإبلاغ عنها هي تضيق اللحم والناصور ، وكانت المضاعفات الأخرى نادرة. لم يتم الإبلاغ عن أي مضاعفات متعلقة بالقسطرة.

الاستنتاجات: قد يؤدي تغيير موضع القسطرة بعد الإزالة غير المقصودة إلى اضطراب مفاغرة أو ناسور. يجب إدخال القسطرة داخل المثانة بدلاً من جعلها دعامة مجرى البول. كانت مزايا تقنيتنا هي القسطرة الأكثر ثباتًا، حيث تم تصنيع القسطرة بأقصر وقت ممكن مما يقلل من فرصة الانسداد ، ويمكن التعامل مع القسطرة بسهولة أكبر حيث يمكن استخدام المنديل بسهولة، وسهولة إزالة القسطرة.

الكلمات المفتاحية: المبال التحتاني، القسطرة البولية، الإزالة غير المقصودة للقسطرة، مضاعفات المبال التحتاني، مضاعفات القسطرة، تضيق اللحم.