

## THE USE OF MOSQUITO NET FOR REPAIRING ABDOMINAL HERNIAS IN ANGORA GOATS

MOHAMMED S. MOHAMMED and M. I. YASIN

Dept. of clinical sciences, College of Veterinary Medicine, University of Dohuk, Kurdistan Region-Iraq

*(Received: May 21, 2018; Accepted for Publication: November 1, 2018)*

### ABSTRACT

One of the most common types of operations performed worldwide in human and animal practice is the repair of abdominal hernias. Hernias can be repaired either by herniorrhaphy or hernioplasty. The aim of this study was to investigate the effectiveness and safety of mosquito net in comparison to commercial mesh for repair of induced hernias in ten adult female Angora goats divided into two equal treatment groups (each of 5 animals). In each group, full thickness abdominal wall defects was created then repaired by commercial polypropylene mesh (PPM) in one group and perlon mosquito net (PMN) in the other.

The results showed no deference in the clinical and surgical outcome between the two groups with no postoperative complications.

Adhesion of the omentum to both mesh types was detected in all animals. Histological examination revealed vascularized fibrous connective tissue formation around the mesh filaments. Chronic inflammatory reaction was detected in all tissue samples from the center of the meshes of both groups and from the interface between the meshes and the animal tissues but it was more evident in hernias repaired by PMN with many foreign body giant cells. In conclusion, PMN can be used to repair abdominal hernias in small ruminants safely as a cheap alternative to the relatively expensive PPM.

**KEYWORDS:** Hernial repair, Polypropylene mesh, Mosquito net

### INTRODUCTION

Repair of abdominal hernias is one of the most common types of operations performed worldwide in human and animal practice. To avoid incarceration and strangulation of the hernial contents, surgery is the best method for treating hernias either by primary closure that approximates the edges of the hernial ring together under tension (open reduction or herniorrhaphy) using different suture patterns and suture materials [1] and [2] or by tension free repair using prosthetic meshes (hernioplasty) which become obligatory to prevent reherniation if hernia closure is impossible and chances of successful repair by simple suturing is poor because of weakened tissue around the hernial ring, too large ring with rounded edges or previously repaired hernias that have failed [3], [4] and [5].

In human, surgical techniques using plastic fiber mesh or net closures are the method of closure for all but the smallest (< 4cm) abdominal defects [6]. Hernioplasty becomes more popular for repairing direct and indirect inguinal, large incisional and ventral hernias by open

hernioplasty or by intraperitoneal laparoscopic hernioplasty, [7] and [8].

Hernioplasty is also used to repair many types of hernias in different animal species like diaphragmatic, abdominal and incisional hernias in horses [9], [10], and [11], umbilical hernias in calves [4], and perineal hernia in dogs [12] and [13].

Annually, several cases of ventrolateral abdominal hernias in small ruminants are referred to our department having large irregular and thin hernial rings with ruptured peritoneum causing bowl and omentum to collect subcutaneously. The Repair of such hernias by primary closure required too much tension on hernial rings which was followed by high rates of reherniation. Repair of such hernias by prosthetic meshes is the only option to obtain desirable results and to salvage the animals especially young, fertile and high milk producing and lactating animals.

Polypropylene (Marlex) is the most widely used mesh for hernia repair [14], [15] and [4], and it is the only mesh used in our local human hospitals. Because the economic value of these small ruminants does not justify mesh and

treatment costs, the owners preferred to slaughter their animals rather than to pay for this relatively expensive mesh.

Mosquito nets of variable polymers are now used in developing countries as cheap alternative to repair inguinal hernias in human with good short and long term clinical outcomes [16], [17], and [18].

The aim of this study is to detect surgical outcome, tissue reaction, and effectiveness of mosquito net for repairing induced abdominal hernias at the ventrolateral region in Angora goats in comparison to polypropylene mesh and to detect the safety of the mosquito net for future use in clinical cases of different types of animal hernias in Kurdistan region/ Iraq.

## MATERIALS AND METHODS

This study was carried out in the department of Medical Science/ College of Veterinary Medicine/ Dohuk University/ Kurdistan region/ Iraq.

### Animals:

For this study, ten, 8-10 month-old apparently healthy mature non pregnant female Angora goats weighing 15-20 kg was used. The animals were housed in a single pen and fed barely and hay (1:2) and water ad libitum. The animals were monitored for 2 weeks and physically examined to determine their health status. The animals were randomly allocated to two equal treatment groups 1 and 2 (each of 5).

### Prosthetic materials

The types of meshes used were:

1. Commercial monofilament polypropylene mesh (PPM) (PROPY-mesh, Atramat, Mexico, size 30x30 cms) in a sterilized package by ethylene oxide.
2. Non-insecticide impregnated multifilament perlon mosquito net (PMN) (nylon 6 or poly caprolactam/China).

The meshes were cut into 10x10 cm pieces; each was sterilized two times before use in separate package by autoclave at 130C° for 15 minutes.

All animals underwent laparotomy to create abdominal defects and followed by repair 2 weeks later either by PPM in group 1, or by PMN in group 2.

### Preoperative preparations

For inducing and repairing the abdominal defects, food and water was withheld before surgery for 24 and 12 hours respectively. Procaine penicillin (30 mg/kg) and dihydrostreptomycin sulphate (10 mg/kg) (Pen & Strep® Norbrook laboratories GB limited) was given intramuscularly one hour before the operation and for 5 days thereafter. The animals were positioned in right lateral recumbency. The left flank and the ventrolateral abdominal region were prepared aseptically (clipping, shaving and scrubbing by chlorhexidine and then by ethyl alcohol). Anesthesia by field block was performed inclosing the surgical field using about 10-12 ml of 2% lidocaine hydrochloride with intravenous injection of xylazine (0.05 mg/kg).

### Surgical procedures

To induce the abdominal defects, each animal underwent ventrolateral laparotomy via a straight 12 cm longitudinal skin and subcutaneous incision at the same level with and 3 cm anterior to the left stifle joint.

In each group, 8x3 cm full thickness abdominal wall excision including the peritoneum was created.

The subcutaneous tissue was then sutured using simple continuous No.0 polyglycolic acid. The skin was closed with interrupted horizontal mattress suture No.0 polypropylene.

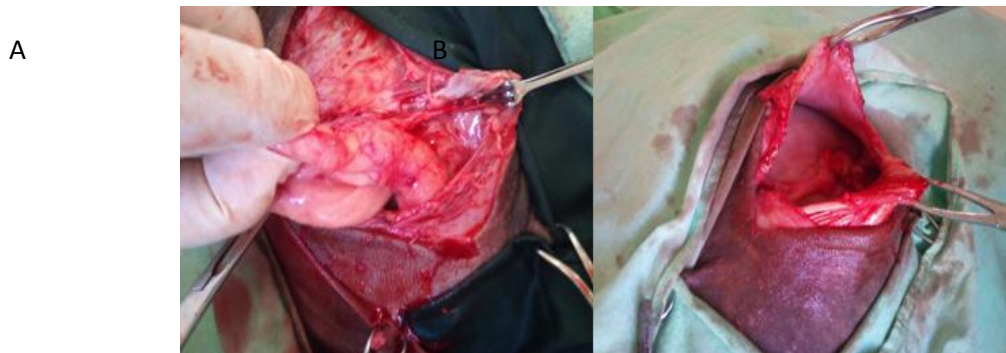
To repair the induced hernias (fig.1), the abdominal cavity of each animal was reentered two weeks after inducing the hernia.



**Fig. (1):** The induced hernia 2 weeks postoperatively.

After excision of the healed skin scar of the primary surgery, the edges of the abdominal defect were identified and any adhesion to the

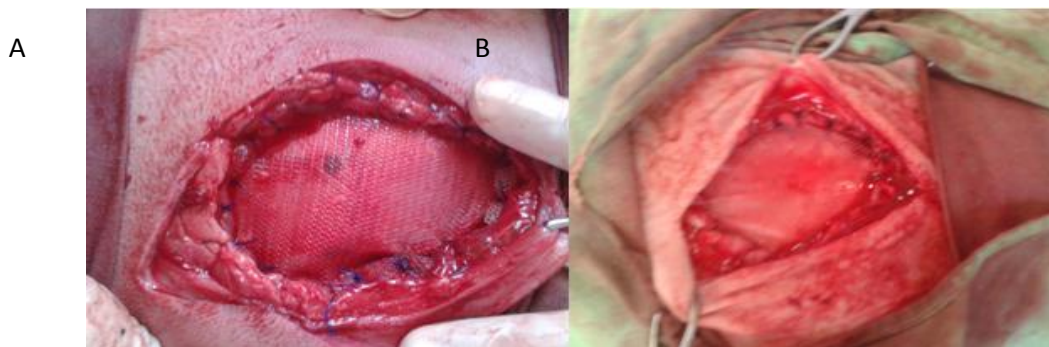
defect was dissected free (fig. 2). The defects were repaired by PPM in animals of group 1 and PMN in group 2.



**Fig. (2):** A: dissecting omental adhesion from the abdominal defect.  
B: preparation of the abdominal defect for repair.

In each group, the mesh was fixed to the abdominal defect to be in direct contact with the omentum. The mesh was cut larger than the defect to extend for about 1 cm over the edges of the

defect on all directions. With applying a moderate tension, the mesh was secured circumferentially with the edges of the defect using simple interrupted No.1 polypropylene suture (fig.3).



**Fig. (3):** Repair of the induced hernias by: A: PPM.  
B: PMN.

The overlying tissues and the skin were then closed to cover the mesh. Drain tube was not used to avoid retrograde infection.

Postoperatively, the animals were allowed to have food and water free choice with daily wound dressing by povidone iodine and antibiotic spray.

The animals were monitored with regards to physical activity, food intake, body temperature, wound complications and reherniation daily till the removal of skin stitches (ten days after the operation) and once weekly till animal slaughter 6 months after mesh implant.

After slaughtering, the skin in each animal was bluntly dissected to expose the whole surgical area to detect the presence of gross infection or any sign of mesh rejection. The abdominal cavity was

opened through a ventral midline abdominal incision and was inspected for the presence of infection and adhesions between the surgical site (the mesh) and the omentum. The whole surgical area was excised in one block with normal tissues from the four surrounding borders. Tissue samples obtained from the interface between the mesh and the edges of the abdominal defect, from the center of the implanted mesh, and from the normal surrounding tissues were fixed in 10% formaldehyde, processed and imbedded in paraffin wax. Paraffin sections were cut (5  $\mu$ m thick) and stained with haematoxylin and eosin and Masson trichrome stain for histopathological examination in the central laboratory of Azadi hospital/ Dohuk/

Iraq to detect healing process, tissue ingrowth, inflammatory and foreign body reaction.

## RESULTS

No gross change in the texture and size of the meshes and no distortion were observed after sterilization by autoclave and the meshes remained robust and did not fray.

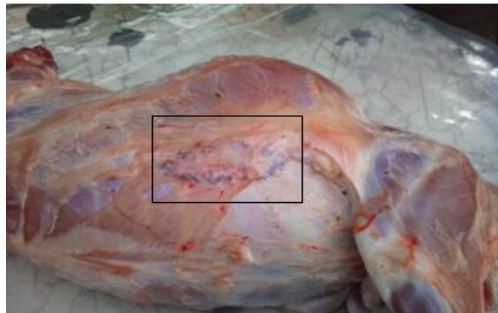Postoperatively, all animals of both groups survived the operation of hernia creation and repair uneventfully. During the follow up period, all animals were normal concerning food intake, physical activity, body temperature, and wound healing. Clinically, at the first postoperative day,

various degrees of edema were seen in all animals and subsided 6-8 days later. Subcutaneous hematoma was found only in one animal of group I in the first postoperative day which was treated by aseptic needle aspiration. No wound infection, fistulae, wound dehiscence or reherniation were detected in all animals.

Postmortem examination:

At the slaughter time, the weight of the animals ranged from 35-40 kg.

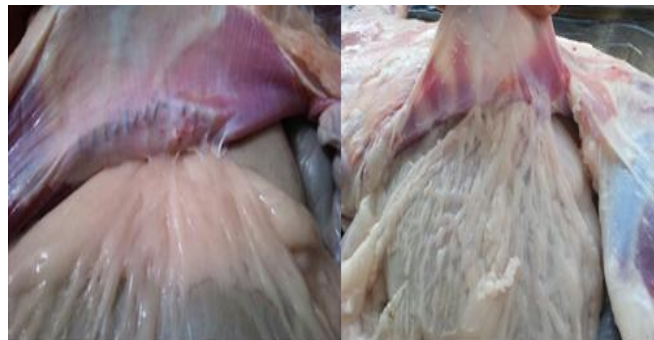No gross infection or abscesses was observed at the surgical areas in all slaughtered animals and the abdominal wall integrity was preserved (fig. 4).



**Fig. (4):** The surgical area after dissecting the skin

No mesh displacement, peripheral detachment, shrinkage, or wrinkling was observed at the surgical area. The visceral surfaces of the

implanted mesh showed adhesions to the omentum (fig. 5).

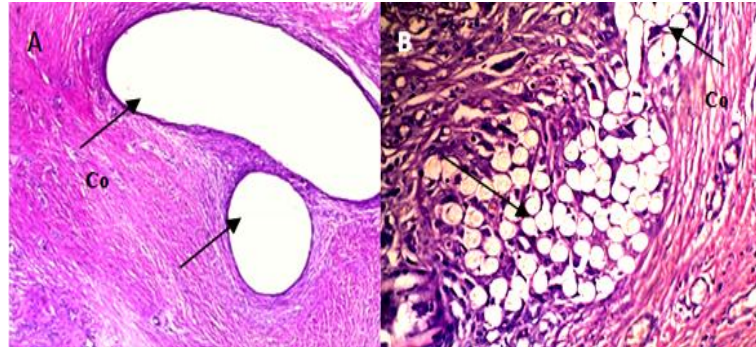


**Fig. (5):** Omental adhesion to the visceral surface of the meshes

Microscopic examination of tissues taken from the center of the implanted mesh (fig.6A and B) and from the tissue-mesh interface (fig.7 and 8) revealed the formation of concentrically organized connective tissue around the mesh filaments composed of bundles of collagen fibers with many fibroblasts, blood capillaries and chronic

inflammatory reaction with infiltration of lymphocytes and macrophages (fig.9). Macrophages were seen adherent to the mesh filaments.

Foreign body giant cells were seen more with PMN meshes (fig.11).

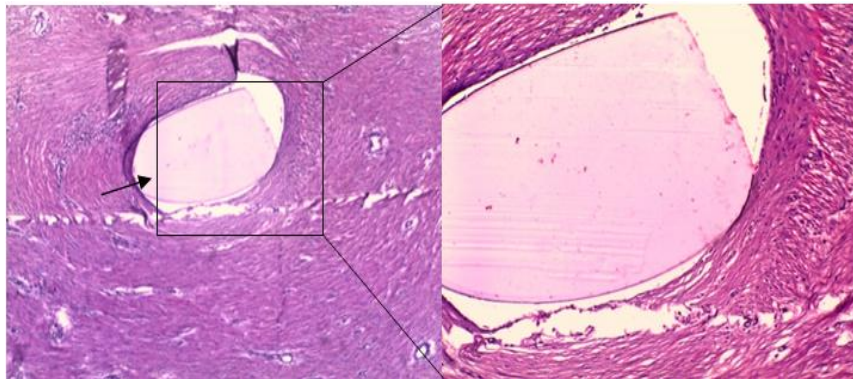


**Fig. (6):** The central part of the implanted meshes

A: PPM. H&E. X4.

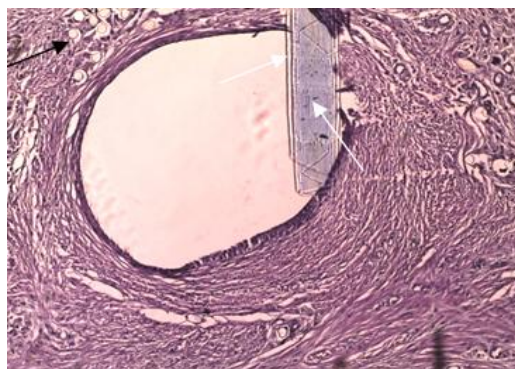
B: PMN. H&E. X20

Connective tissue (Co) is formed around the meshes (arrows).

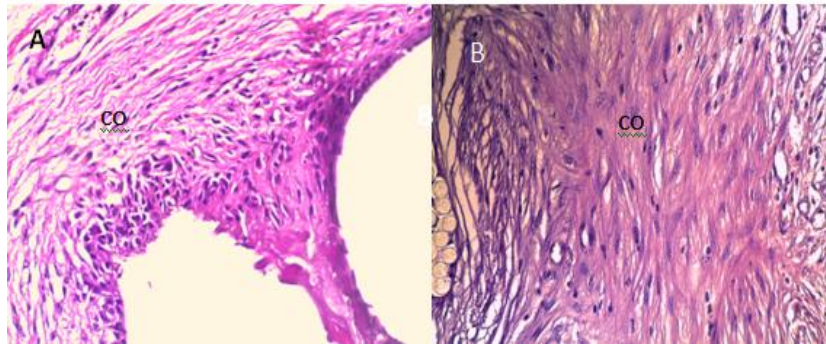


**Fig. (7):** Left: Interface between the polypropylene mesh and the animal tissue. A remnant of polypropylene suture used to fix the mesh with the abdominal defect is indicated by the arrow. H&E X4.

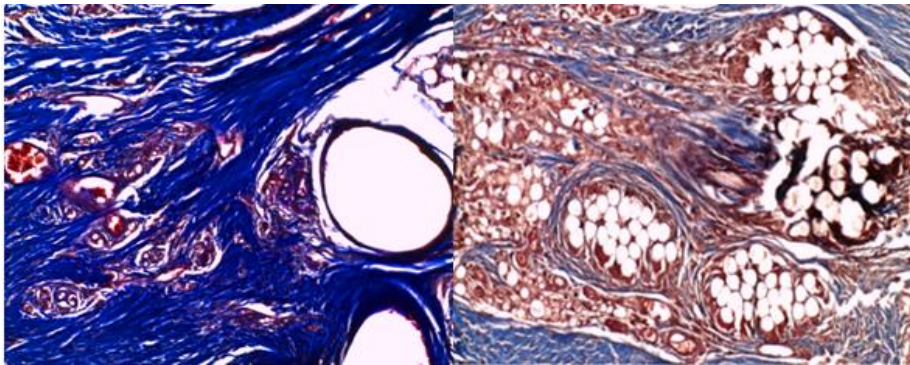
Right: connective tissue formation surrounding the mesh.



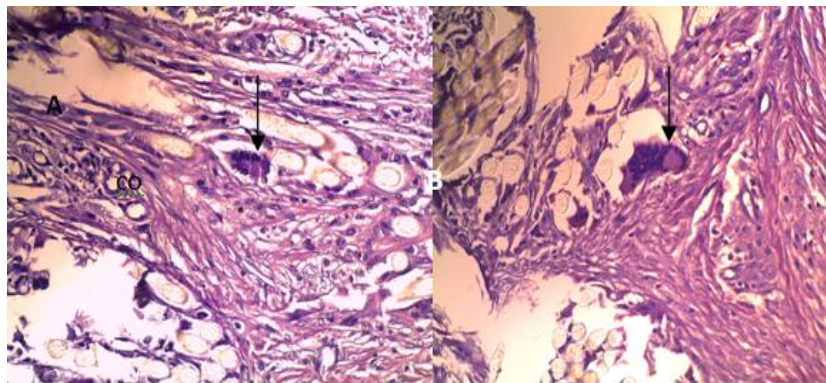
**Fig. (8):** Interface between the mesh (black arrow) and the animal tissue. A remnant of polypropylene suture used to fix the mesh with the abdominal defect is indicated by the white arrow. H&E. X10



**Fig. (9):** Presence of inflammatory cells and new blood vessels in the connective tissue (co) and around the PPM(A) and PMN (B) mesh filaments. H&E. X10



**Fig. (10):** Thicker connective tissue surrounding the PPM pores (left figure) than that seen around the PMN pores (right figure). Masson trichrome stain x10



**Fig. (11):** Foreign body giant cells (arrows). H&E. X20

Polypropylene mesh elicited a moderate chronic inflammation with adequate fibrous tissue incorporation. Lower foreign body reaction (FBR) was observed in PPM than with PMN. All tissues surrounding the surgical site were histologically normal with minimal inflammatory reaction.

## DISCUSSION

The main indications for using prosthetic meshes for hernia repair is to restore normal

anatomy and function of the abdominal wall and reduce the rates of hernia recurrence and postoperative pain [19], [20], [21] and [22].

In developed countries, many varieties of mesh materials are innovated but none of them is considered ideal, all have some undesirable effects and the selection of the mesh depend on the experience and preference of the surgeons and the mesh cost [23].

In Duhok region, commercial polypropylene mesh is the only type available in the local market

and extensively used in local human hospitals for hernia repair. It is inert and has high tensile strength but it is not flexible [24].

Short and long term complications were reported in some human and animal studies after polypropylene mesh implantation, they include seroma formation [25] and [26], surgical site infection and reherniation, with colic in horses and pain in human [27], [28], [10],[29], and [30], contraction/shrinkage of the mesh [31], adhesion [32], [33] and [27], and enterocutaneous fistula formation especially when the mesh is placed intra-abdominally adjacent to the viscera which is a serious complication requiring removal of the mesh [34], [35], [36], and [37].

In the present study, no complications were detected in both treatment groups during the follow up period. It is difficult to infer whether the animals felt pain or not, but even if there was pain, it was not so acute to cause depression and anorexia; all animals were active, continued to gain weight during the study period with normal body temperature and appetite.

Chronic inflammatory reaction was noted in tissue samples from both groups in which macrophages were the predominant cell type found with many foreign body giant cells observed more with PMN.

Many studies reported persistence of chronic inflammation many years after polypropylene implantation [38] and [39].

Chronic inflammation is caused by persistent inflammatory stimuli caused by the implants [40] and is characterized by the presence of macrophages, monocytes, and lymphocytes, with the proliferation of blood vessels and connective tissue [41] and [42].

Once the mesh is implanted into the body, a series of reactions will occur in the host surrounding tissues which include local injury, blood mediated interaction and initiation of inflammatory response, matrix formation, acute inflammation, chronic inflammation, granulation tissue development, foreign body reaction and fibrous capsule development [40] and [43].

The presence of macrophages, lymphocytes, foreign body reaction and granulation tissue formation is considered to be the normal wound healing response to the implants [44] and [40]. Foreign body reaction that consists of macrophages and foreign body giant cells may persist for the life of the implants. The presence of an implant with its foreign body reaction leads to

fibrous encapsulation surrounding and isolating the mesh from the local host tissue environment [44].

Adhesions are usually an unavoidable common consequence of laparotomy seen after 67- 93% of intra-abdominal surgery [45]. It occurs mainly due to peritoneal trauma and injury during surgery, inflammatory diseases or exposure to foreign materials like polypropylene meshes which is considered as a strong stimulus for the development of permanent adhesions [46], [47], [48]and [49].

Adhesion is considered as a part of the normal healing process after parietal or visceral peritoneal damage which initiates an inflammatory response that involves biochemical and biomechanical factors leading to fibrinous exudate formation, increase in the deposition of fibrin matrix, cytokine production, cell migration, vascular oedema and suppression of fibrinolytic activity by inhibiting plasminogen activator activity leading to the maturation of the fibrin matrix into fibrous adhesions [50] and [51].

When the mesh is placed intraperitoneally, most of the adhesions occur between the omentum and the mesh

In our study, the omentum was the only structure seen attached to the visceral surface of the mesh. Many studies showed that placing the omentum between the viscera and the mesh is considered advantageous in preventing intestinal adhesion which causes intestinal erosion, fistulation and obstruction [52] and [53].

In our opinion, mesh implantation is attempted only if the hernia recurs after primary closure or when the hernial ring is too large to be closed by primary apposition.

The procedure of mesh implantation is easy to perform and do not require special experience. Short term follow-up revealed no difference in the surgical outcome when PPM and PMN were used to repair the induced hernias.

Many studies revealed no significant difference regarding short term complications when mosquito nets were used for inguinal and incisional hernias in comparison with commercial meshes [54].

The results of this study revealed that PMN can be used to repair abdominal hernias in animals. It is cheaper than polypropylene mesh and can be sterilized by autoclave without grossly affecting its physical characters and short term

complications were not recorded when implanted within the animal tissue.

In this study, Angora goats were used as research model because of their widespread availability, easy to handle and house, cheaper to purchase and feed than other types of ruminants.

## REFERENCES

- Keown, G. H. (1976). The abdominal wall. In: Textbook of large animal surgery edited by Oehme, F.W. and Prier, J. E. The Williams & Wilkins comp. Baltimore. pp: 173-176.
- Ammann, K. and Becker, M. (1988). Suture techniques for hernias. In: Textbook of large animal surgery. 2<sup>nd</sup> ed. edited by Oehme, F. W. Williams & Wilkins. Baltimore. pp 135-136.
- Nelson, D.R. (1988). Prosthetic materials in hernia repair. In: Textbook of large animal surgery. 2<sup>nd</sup> ed. edited by Oehme, F. W. Williams & Wilkins. Baltimore. pp: 394-395.
- Baxter, G. M. (2004). Hernias/Umbilicus. In Farm animal surgery edited by Fubini, S. and Ducharme, N. Saunders, USA, pp: 483.
- Bendavid, R. (1994). The need for mesh. In: Prosthesis and abdominal wall hernias. Austin. Landes. R.G. comp. pp 116-122.
- Williams, N.S.; Bulstrode, C.J.K.; O’Connell, P.R. (2008). Incisional hernia. In: Bailey and Loves Short practice of surgery. 25<sup>th</sup> edition. Hodder Arnold, London. pp: 987- 988.
- Sewell, R. W.(1996). Ventral hernia repair. In: Operative laparoscopy and thoracoscopy edited by MacFadyen, Jr. B.V. and Ponsky, J. L. Lippincott-Raven publisher, Philadelphia. pp: 807.
- Sanchez, L. J.; Bencini, L.; Morett, R. (2004). Recurrence after laparoscopic ventral hernia repair: results and critical review. *Hernia* 8, 138-143.
- Scott, E. A. and Fishback, W. A. (1976). Repair of diaphragmatic hernia in a horse. *J.A.V. M.* 168: 45-47.
- Elce, Y. A.; Kraus, J.; Orsini, J. A. (2005). Mesh hernioplasty for repair of incisional hernias of the ventral body wall in large horses. *Equine Vet. Educ.* 17: 252-256.
- Kelmer, G. and Schumacher, J. (2008). Repair of abdominal wall hernias in horses using primary closure and subcutaneous implantation of mesh. *Vet. Rec.* 163:677-679.
- Clarke, R. E. (1989). Perineal herniorrhaphy in the dog using polypropylene mesh. *Aust. Vet. Pract.* 19:8-14.
- John Martin, K.D.; Sarangom, S.B.; Philip, S.B.; Kankonkar, A. P. (2012). Repair of recurrent perineal hernia using polypropylene mesh in a dog. *J.Vet.Anim.Sci.*2012, 43:59-61.
- Molloy, R.G.; Moran, K.T.; Waldron, R.P.; Brady, M.P.; Kirwan, W.O. (1991). Massive incisional hernia: abdominal wall replacement with Marlex mesh. *Br.J.Surg.* 78:242-244.
- Leber, G. E.; Garb, J. L.; Alexander, A.I.; Reed, W. P. (1998). Long term complications associated with prosthetic repair of incisional hernias. *Arch. Surg.* 133(4): 378-382.
- Daou, R. (2007). Commercial mesh versus nylon mosquito net for hernia repair. *World J. Surg.* 31(4), 860.
- Kingsnorth, A. N. (2007). Commercial mesh vs. nylon mosquito net for hernia repair. *World J. Surg.* 31(4), 859.
- Clarke, M.G.; Oppong, C.; Simmermacher, R.; Park, K.; Kurzer, M.; Vanotoo, L.; Kingsnorth, A. N. (2009). The use of sterilised polyester mosquito net mesh for inguinal hernia repair in Ghana. *Hernia* 13(2), 155–159.
- Luijendijk, R. W.; Hop, W. C. J., Van den Tol, M. P.; de Lange, D.C.D.; Braaksma, M.M.J.; Ijzermans, J.N.M.; Boelhouwer, R. U.; de Vries, B. C.; Salu, M. K.M.; Wereldsma, J. C. J.; Bruijninx, C. M.A.; Jeekel, J. (2000). A comparison of suture repair with mesh repair for incisional hernia. *N. Engl. J. Med.* 343: 392.
- The EU Hernia Trialists Collaboration. (2002). Repair of groin hernia with synthetic mesh: meta-analysis of RCT. *Ann Surg.* 235:322–332.
- Schumpelick, V. and Klinge, U. (2003). Prosthetic implants for hernia repair. *Br. J. Surg.* 90: 1457-1458.
- Burger, J. W.; Luijendijk, R. W.; Hop, W. C.; Halm, J. A.; Verdaasdonk, E. G.; Jeekel, J. (2004). Long term follow-up of randomized controlled trial of suture versus mesh repair of incisional hernia. *Ann. Surg.* 4, 578-585.
- Eriksen, J.R.; Gögenur, I.; Rosenberg, J. (2007). Choice of mesh for laparoscopic ventral hernia repair. *Hernia*, 11(6):481-492
- Brown, C.N. and Finch, J.G. (2010). Which mesh for hernia repair? *Ann. R. Coll. Surg.* 92(4): 272-278.
- Bowman, K.L.; Birchard, S.J.; Bright, R.M. (1998). Complications associated with the implantation of polypropylene mesh in dogs and cats: a retrospective study of 21 cases (1984-1996). *J. Am. Animal hospital Assoc.* 34(3):225-233.
- Heniford, B.T.; Park, A.; Ramshaw, B.J.; Voeller, G. (2003). Laparoscopic repair of ventral hernias. Nine years’ experience with 850 consecutive hernias. *Ann. Surg.* 238(3):391-400.
- Tulleners, E.P. and Fretz, P.B. (1983). Prosthetic repair of large animal wall defects and food animals. *J.Am.Vet.Med. Ass.*182: 258-262.
- Paajanen, H. and Hermunen, H. (2004). Long-term pain and recurrence after repair of ventral incisional



- hernias by open mesh: clinical and MRI study. *Langenbecks Arch. Surg.* 389(5):366-370.
- Freeman, D.E. (2005). Management of ventral incisional hernias in large horses: A surgical challenge. *Equine Vet. Educ.* 17: 247-251.
- Whitfield-Cargile, C.M.; Rakestraw, P.C.; Hardy, J.; Cohen, N.D.; Davis, B.E. (2011). Comparison of primary closure of incisional hernias in horses with or without the use of prosthetic mesh support. *Equine Vet. J.* 43:69-75.
- Gonzalez, R.; Fugate, K.; McClusky, D.3rd; Ritter, E.M.; Lederman, A.; Dillehay, D.; Smith, C.D.; Ramshaw, B.J. (2005). Relationship between tissue ingrowth and mesh contraction. *World J. Surg.* 29(8): 1038-1043.
- Matthews, B.D.; Pratt, B.L.; Pollinger, H.S.; Backus, C.L.; Kercher, K.W.; Sing, R.F.; Heniford, B.T. (2003). Assessment of adhesion formation to intra-abdominal polypropylene mesh and polytetrafluoroethylene mesh. *J. Surg. Res.* 114(2):126-132.
- Novitsky, Y.W.; Harrell, A.G.; Cristiano, J.A.; Paton, B.L.; Norton, H.J.; Peindl, R.D.; Kercher, K.W.; Heniford, B.T. (2007). Comparative evaluation of adhesion formation, strength of ingrowth, and textile properties of prosthetic meshes after long-term intra-abdominal implantation in a rabbit. *J. Surg. Res.* 140(1): 6-11.
- Kaufman, Z.; Engelberg, M.; Zager, M. (1981). Fecal fistula: a late complication of Marlex mesh repair. *Dis. Colon Rectum.* 24:543-544.
- Miller, K. and Junger, W. (1997). Ileocutaneous fistula formation following polypropylene mesh hernia repair. *Surg. endosc.* 11(7):772-773.
- Morris-Stiff, G.J. and Hughes, L.E. (1998). The outcome of nonabsorbable mesh placed within the abdominal cavity: literature review and clinical experience. *J. Am. Coll. Surg.* 186:352-367.
- Cassar, K. and Munro, A. (2002). Surgical treatment of incisional hernia. *Br. J. Surg.* 89:534-545.
- Klinge, U.; Klosterhalfen, B.; Müller, M.; Schumpelick, V. (1999). Foreign body reaction to meshes used for the repair of abdominal wall hernias. *Eur. J. Surg.* 165(7): 665-673.
- Oana, L.; Ober, C.; Peştean, C.; Taulescu, M.; Miclăuş, V.; Cătoi, C.; Oros, A.; Oros, D. (2010). Integration histology of polypropylene mesh in perineal hernia in dogs – A case study. *Annals of RSCB.* XV(1):174-177.
- Anderson, J.M. (2001). Biological response to materials. *Annu. Rev. Mater. Res.* 31:81-110.
- Johnston RB Jr. (1988). Monocytes and macrophages. *N. Engl. J. Med.* 318:747-52
- Williams GT, Williams WJ. (1983). Granulomatous inflammation – a review. *J. Clin. Pathol.* 36:723-33.
- Anderson, J.M.; Rodriguez, A.; Chang, D.T. (2008). Foreign body reaction to biomaterials. *Semin Immunol.* 20(2):86-100.
- Lin, P.H.; Hirko, M.K.; von Fraunhofer, J.A.; Greisler, H.P. (1997). Wound healing and inflammatory response to biomaterials. In: *Wound closure. Biomaterials and devices.* Edited by Chu, C.C.; von Fraunhofer, J.A.; Greisler, H.P. USA, CRC Press. LLC. pp: 12-17.
- Risberg, B. (1997). Adhesions: preventive strategies. *Eur. J. Surg. Suppl.* 577:32-39.
- Menzies, D. (1993). Postoperative adhesions: their treatment and relevance in clinical practice [review]. *Ann. R. Coll. Surg. Engl.* 75:147-53.
- DiZeraga, G.S. (1994). Contemporary adhesion prevention. *Fertil. Steril.* 61: 219-235.
- Luijendijk, R.W.; de Lange, D.C.; Wauters, C.C.; Hop, W.C.; Duron, J.J.; Paillet, J.L.; Camprodon, B.R.; Holmdahl, L.; van Geldorp, H.J.; Jeekel, J. (1996). Foreign material in postoperative adhesions. *Ann. Surg.* 223:242-248
- Baptista, M.L.; Bonsack, M.E.; Delaney, J.P. (2000). Sefrafilm reduces adhesions to polypropylene mesh. *Surg.* 128(1):86-92.
- Holmdahl, L.E.; Al-Jabreen, M.; Risberg, B. (1994). Role of fibrinolysis in the formation of postoperative adhesions. *Wound Repair Regen.* 2(3):171-176.
- diZeraga, G.S. and Campeau, J.D. (2001). Peritoneal repair and post-surgical adhesion formation. *Hum. Reprod. Update.* 7(6): 547-555.
- Celdrán, A.; García-Ureña, M.A.; Bazire, P.; Marijuan, J.L. (1996). The use of omentum in mesh repair of ventral hernias. *Am. Surg.* 62 (6): 443-445.
- Karabulut, B.; Sönmez, K.; Türkyilmaz, Z.; Demiroğullar, B.; Karabulut, R.; Sezer, C.; Sultan, N.; Başaklar, A.C.; Kale, N. (2006). Omentum prevents intestinal adhesions to mesh graft in abdominal infections and serosal defects. *Surg. Endosc.* 20(6): 978-982.
- Freudenberg, S.; Sano, D.; Ouangré, E.; Weiss, C.; Wilhelm, T. J. (2006). Commercial mesh versus nylon mosquito net for hernia repair. A randomized double-blind study in Burkina Faso. *World J. Surg.* 30(10): 1784-1789.

پوخته

نیک ژ بهر به لافترین نشته رگه ریا ل سهرانسهر جیهانی دنوژداریا مروقی و گیانه وه راندا راسته کرنا فتقین زکی نه. فتق دبیت بهیته راتفه کرن ب هیرنیورافی یان ب هیرنیوپلاستی. نارمانچ ژ فئی فه کولینی دیفجونا کاریگه ری و نیمیا کولی پیشیا ب بهر اوردی دگه ل تورا بازرگانی بو راسته کرنا دهه بزنین مه رزی بین پیگه هشتی بین می بین هاتینه فتقویبکرن، هاتینه دابهش کرن بو دوو کومین وهك ههف (هه رنیک ژ 5 گیانه وه ران) دهه ر کومه کئی دا شیواندنهك ب ستیراتیا تماما دیوارئ زکی پهیدا کر و پاشی هاته راسته کرن ب پولیپروپلینی بازرگانی د کومه کئی دا و پیرلون کولی پیشیا دکوما دی دا. نه نجامان چ جوداهیین کلینیکی و نشته رگه ری دناف بهرا ههردوو کومان دیارنه کر و بی ئالوزیین پشتی نشته رگه ری. بیگه نسیانا پهردا بهزی ب ههردوو جورین تورا فه هاته دبیتن دهه می گیانه وه راندا. د پشکینا هیستولوجی دا، دروستبونا شانیا ریشالیا به سته ر ل دور ریشالین توری دیارکر. کارفه دانا هه ودانا دوم دریز هاته دبیتن دهه می نموونین شانیا پاندا د نا فه ندا توراندا دههردوو کومان دا و جهئ تور و شانین گیانه وه ری بیگه هاتینه گریدان به لئ پتر یا رون بو د فتقین راسته کری ب پیرلون کولی پیشیا و دگه ل هژماره کا خانه بین ته نین خانه بین مازن. ددهر نه نجام دا پیرلون کولی پیشیا د شیین بکاریبین بو راسته کرنا فتقین زکی د ته رش و ته والئ بجیک دا بسلامه تی وهك جه گره کئی نه رزان بو تورا پولیپروپلینی بی گران بها تا راده کی.

#### استعمال الناموسية لتصلیح الفتوق البطنية

الخلاصه

إحدى الأنواع الأكثر شيوعاً من العمليات الجراحية حول العالم في الممارسة الطبية الإنسانية والحيوانية، تصلیح الفتوق البطنية. الفتوق يُمْكِنُ أَنْ تُصَلِّحَ أَمَا ب هيرنيورافي أو هيرنيوبلاستي. الهدف من هذه الدراسة كَانَ لِتَحْرِى التَّأثيرَ وَأَمَانَ الناموسية بالمقارنة مع شبكة تجارية لتصلیح الفتوق المستحثة في عشرة أناث من عنزات أنغورة البالغة قَسَمْتُ إلى مجموعتين مساويتين (5 حيوانات لَكُلِّ مجموعة). في كُلِّ مجموعة، كونت عيوب بِسْمَكٍ كامل في جدار البطن ثمَّ صَلِّحْتُ بِشبكة بوليپروپلین تجارية (PPM) في مجموعة واحدة وناموسية برلون (PMN) في المجموعة الأخرى. النَّتائج لم تظهر أي اختلافات السريرية والجراحية بين المجموعتين وبدون تعقيدات ما بعد الجراحة. إلتصاق الثرب إلى كلتا أنواع الشبكتين إكتشف في كُلِّ الحيوانات. كَشَفَ فَحصُ النسيجي تشكيل نسيج وعائي الليفي الرابط حول الياف الشبكة. رَدَّ الفعل الالتهابي المزمَن إكتشفَ في كُلِّ عينات النسيجية مِنْ مركز شبكات في كلتا المجموعتين وَمِن الوصلة بين الشبكات والأنسجة الحيوانية لَكِنَّه كَانَ أَكثَر وضوحاً في الفتوق التي اصلحَ ب PMN مع العديد من خلايا الجسم الغريب العملاقة. نتيجةً لذلك، PMN يمكن أن يُستعمل لتصلیح فتوق بطنية في المجترات الصغيرة بسلامة كبديل رخيص ل PPM الغالي نسبياً.