

SOCKET SHIELD TECHNIQUE FOR DENTAL IMPLANTS IN THE ESTHETIC ZONE, CLINICAL AND RADIOGRAPHICAL EVALUATION

SANDY ANDRAWS HANA* and OTHMAN ABUBAKIR OMAR**

*Dept. of Maxillofacial Surgery & Periodontics, College of Dentistry, University of Dohuk, Kurdistan Region-Iraq

**Dept. of Oral and Maxillofacial Surgery, College of Dentistry, Hawler Medical University, Kurdistan Region-Iraq

(Received: November 26, 2019; Accepted for Publication: February 17, 2020)

ABSTRACT

Background and objective: The socket shield technique where the buccal fragment of the root is left attached to the socket wall before the dental implant insertion. The purpose of retaining the buccal fragment is to aid in restoring the esthetic natural appearance around dental implant.

Aim: To assess the role of the retention of a buccal part of the root in preserving the pre-implant esthetic and functional condition.

Methods: Forty patients had been enrolled randomly. Twenty cases of socket shield technique as study group and twenty cases of conventional immediate implant as control group, and these two groups were followed up and evaluated for the implant survival, pink esthetic score for the soft tissue related to dental implant, and radiographically with PA and O.P.G in addition to CBCT that aid in finding any pathology or bone defect and the thickness of the buccal bone related to placed implant.

Results: One case failed out of twenty of each group. 95% success rate. With the clinical evaluation of pink esthetic score the socket shield technique showed a higher value that approximates the natural teeth 12.26, while in conventional technique there was decrease in the values of pink esthetic score 9.63. The results of the conventional immediate implant technique were unpredictable, and some of the cases after one year needed soft tissue graft to repair the esthetic defect that was not needed in socket shield technique.

Conclusion: The Socket shield technique could be a good choice and treatment modality for the esthetic zone. It gives the optimum esthetic results but still needs a very experienced surgeon to prevent the complications that are related to this technique.

KEYWORDS: Socket Shield, Bone Loss, Buccal Bone, Esthetic Zone, Pink Esthetic Score.

<https://doi.org/10.26682/sjuod.2020.23.1.8>

INTRODUCTION

After tooth extraction, one of the most common complications is dimensional changes in alveolar ridges which is difficult to be avoided or reversed, so this shrinkage is an unfavorable physiological change for the restorative procedures (1). This bone loss that occurs after extraction mainly in the buccal plate occurs as a result of losing ligament and its related blood vessels, which regarded as important blood supply for the nourishment of buccal plate, especially in anterior maxillary teeth which commonly have a delicate and thin buccal plate (2). And as a result of buccal bone loss, the overlying soft tissue will be negatively affected because it will lose its support and will

shrink as underlying bone resorbed (3). There are some steps during surgical procedures that thought to help in maintaining post-extraction socket by decreasing alveolar bone resorption, for example, atraumatic extraction, socket preservation technique and immediate implant placement (4). Using socket preservation procedures may control ridge resorption to some degree, but that procedure rarely results in complete preservation of the alveolar ridge frame. (5) Also, it is known that immediate implant doesn't act to prevent the buccal bone resorption, so some methods are needed to be used to decrease the effect of that resorption on dental implant like, availability of not less than 2mm width of the buccal bone crest, placing implant palatally and adequate implant diameter

in proportion to the width of the ridge. (6)

It is essential to take in consideration when restoring the area of extracted tooth or teeth either with fixed bridges or dental implant, not just the proper design and shade of crowns or bridges, but also to the soft tissue which includes the papilla and the gingiva keratinization and the harmony of appearance which is very important aesthetically. (7, 8)

The socket-shield technique (SST) which is one of alveolar ridge preservation procedures similar in the principles to the root submerging technique, was first introduced by Hürzeler et al, he described this technique as with keeping a buccal fragment of the tooth that will be extracted, specifically the vestibular portion of the most coronal third of the root, aiming to prevent the buccal cortical bone from resorption (4, 9).

The known advantages of SST are; a minimally invasive technique, help in maintaining hard and soft-tissue contours, minimizes the need soft and hard tissue grafting procedures, shortens the overall treatment duration, the interdental papilla can be preserved by preparing interdental socket shield, and lastly it is a highly promising technique in terms of maintaining pink and white aesthetics and provides a solution for esthetically critical cases such as high lip line (10). There are also some disadvantages or complications with the SST are; Buccal/crestal bone loss, failure of osseointegration, shield exposure/failure, cementum formation on implant surfaces, Pocket formation, inflammation, and mucositis (11).

This study is done to compare the esthetic results between conventional immediate implant placements with the immediate implant placement by the socket shield technique, this evaluation was done with the aid of pink esthetic score.

MATERIALS AND METHODS

This study is conducted with the evaluation of success rate of the socket shield technique in

both esthetic and functional aspects and assess the benefits and shortcoming of this technique, and trying to make an addition information to the data or the knowledge about this technique, as it needs many studies to increase the data about this procedure.

Study Sample

This study is a combined, retrospective comparative study. The sample for this study composed of 40 selected patients according to inclusions and exclusions criteria; these cases were selected from patients visiting the specialized center of dental implant at Rizgary teaching hospital. And these cases were divided into two groups the first group is 20 patients with a socket shield technique and the second group is 20 with a conventional immediate implant. The dental implants used in this study were (Euroteknika) System.

Inclusion Criteria

- The implanted teeth included from the 1st premolar of the right to the left sides in the esthetic zone of the maxilla.
- The selected cases should be medically healthy adult both males and females (ASA classification I-II).
- Age ≥ 25 years old, Non-smoker or mild cigarette smoker, a hopeless anterior tooth with mostly neighboring teeth on the mesial and distal.

Intact buccal periodontal tissues, and finally, the patients should have good oral hygiene.

Materials

Dental syringe, anesthesia cartridge (lidocaine hydrochloride 2%, 1.8 ml), needle, Dental implant surgical kit, Oral surgical kit (scalpel, blade, periosteal elevator, needle holder, scissor, cheek retractor, suturing materials), Dental mirror and periodontal probe, Surgical sucker, Dental implant engine with the handpiece, Turbine and special burs for preparing root shield, Upper anterior forceps, root forceps, elevators, and peristome, Impression materials. As shown in Figures (1) and (2).

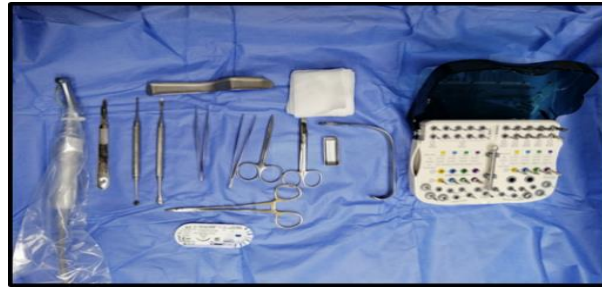

Figure 1: Showing the surgical kit with a dental implant kit.



Fig. (2): Showing special burs used for SST procedures.

Surgical Procedure

- All the patients were asked to rinse their mouths with 12% chlorhexidine for not less than 30 seconds, followed by disinfection of the skin around the mouth with gauze swabbed with povidone-iodine solution.
- After preparing the patients, the conventional immediate implant placement started by giving the required amount of anesthesia needed for the surgery by infiltration technique, then extraction of the tooth was done with minimum trauma to the periodontium then the type I or II sockets was prepared for the placement of the implant.
- While in socket shield technique the crowns of the involved teeth were removed using diamond bur to a level not more than 1 mm above the alveolar crest, to preserve dentogingival fibers intact which result in more esthetic appearance of soft tissue, then the remaining roots were split mesiodistally by special kind of burs so the roots were divided in to buccal and palatal part which is larger size and attached with the apex of the tooth, the palatal part was weakened and removed carefully leaving the smaller buccal piece which was about 2 mm thickness and reduced incisally with approximately the level of the crestal bone.
- when emphasized that the root shield wasn't mobile the tooth socket was prepared for implant placement, and distance was kept from the root shield (about 1-2 mm), then the fixture with appropriate length and diameter was inserted in the prepared site with insertion torque with average of 49Ncm after that abutment or

gingival former were placed, so all SST cases were immediately loaded. What SST results in is implant attached to the bone in palatal, mesial, and distal directions while there is a free distance in the buccal border, so buccally there are cementum, dentin, periodontal ligament, and buccal bone lamella.

- After finishing surgical procedures patient was instructed to continue antibiotic treatment mostly with the amoxiclave tab. 1g twice daily for five days in addition to oral hygiene instructions using 0.12 % chlorhexidine mouth wash for two weeks and to be seen after three months for evaluation and replacement of the temporary crown with permanent one.
- Following up the patients of both SST group and CII group for evaluation was done by obtaining the results of the 38 dental implants in a total of 40 dental implants each group had one case failed, and the teeth had been extracted in study group were 8 central incisors, 6 lateral incisors, and 6 canines, While in the control group were 9 central incisors, 6 lateral incisors, and 5 canines .The gender of the patients was 24 male 16 female, the age ranged from 28 years to 65 years for both female and male with mean age of 51 years, and those cases were formed of 20 cases of SST as study group, and the 20 conventional immediate implanted cases as control group. (Figure 6)
- The dimensions of implants used in the study ranged from 3.5 to 5 with a mean of 4.1mm diameter, and from 11 to 14 in length with an average of 12.3 mm, no graft materials or

membranes were used.

- Provisional rehabilitation was done with acrylic resin for immediate loading cases after one to 4 days of the surgical procedure according to facilities available and lab cooperation. The definitive restorations were porcelain-fused-to-metal cement-retained

restorations that were fabricated 3 to 6 months after.

- Radiographic evaluation for SST cases was done with CBCT to evaluate any problem with the shield and if there is resorption or presence of any pathology related to it, that were obtained at each patient's latest follow-up visit.

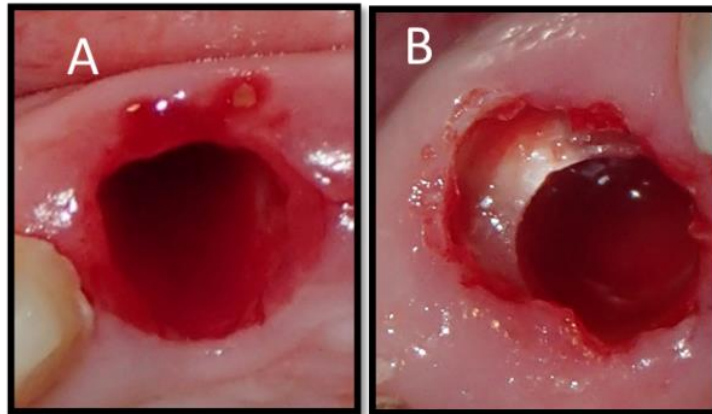


Fig. (3): A) show socket after the tooth removal with conventional technique, B) tooth extraction socket with SST.

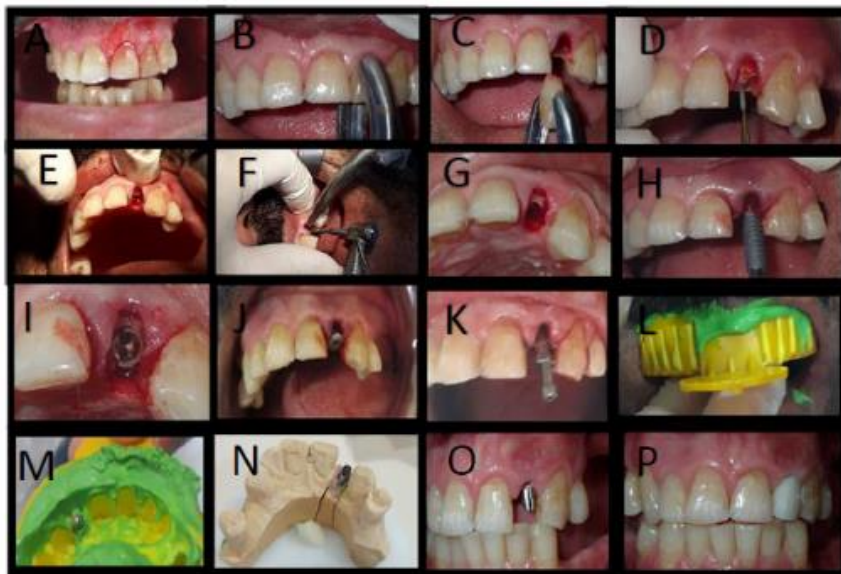


Fig. (4): Illustrated the steps from the beginning of the procedures till insertion of temporary crown of tooth 22; A, B and C: show horizontally fractured crown being removed, D: starting the mesio_distal sectioning with special kind of long bur, E and F: further preparation of the site by leaving the buccal fragment of the root, G: finished site of tooth 22 and ready to insert of implant in the prepared bed, H: implant insertion, I: show implant with the shield, J:gingival former, K: impression post, L and M:taking impression with open tray technique, N:lab work, O and P: insertion of temporary crown then to be replaced by permanent one after 2 to 3 months.

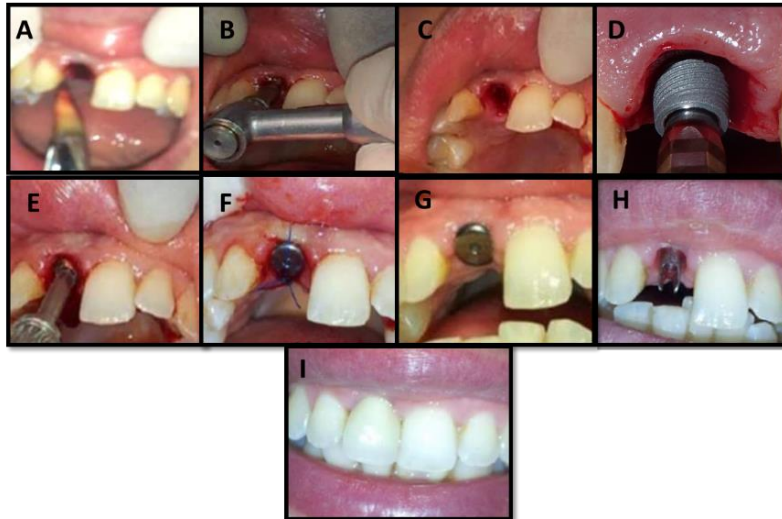


Fig. (5) : **A)** tooth 11 extraction with minimum trauma to the bone and in this technique (**CII**) the tooth removed completely and nothing remain in socket, **B)** implant site preparation, **C)** prepared extraction socket ready for implant insertion, **D) & E)** insertion of the implant, **F)** insertion of the gingival former in the day of surgery, **G)** one week later suture removal, **H)** abutment, **I)** Insertion of the crown after 10 days.

Clinical Evaluation

The implant was evaluated clinically for any mobility, presence of pain, infection, neuropathy, and radiographically to determine

the implant success rate according to the Albrektsson's criteria (Albrektsson et al.; 1986). Also, the soft tissue was evaluated with the pink esthetic score.

Table (1): Distribution of Implanted Teeth. *SST= Socket Shield Technique, **CII= Conventional Immediate Implant.

Treating Strategy	Centrals	Lateral	Canine	Total
SST*	8	6	6	20
CII**	9	6	5	20

Table (2): Torque of the Inserted Implant. *SST= Socket Shield Technique, **CII= Conventional Immediate Implant.

Treating Strategy	Insertion Torque	Immediate Loading	Delayed Loading
SST*	49 N cm	19	—
CII*	51 N cm	18	1

RESULTS

Forty healthy adult patients within the inclusive criteria and age ranged between 28

years and 65 years for both males and females, with mean age of 51 years enrolled in this study. According to their sex, the males were 26, and the females were 14. As shown in Figure (4).

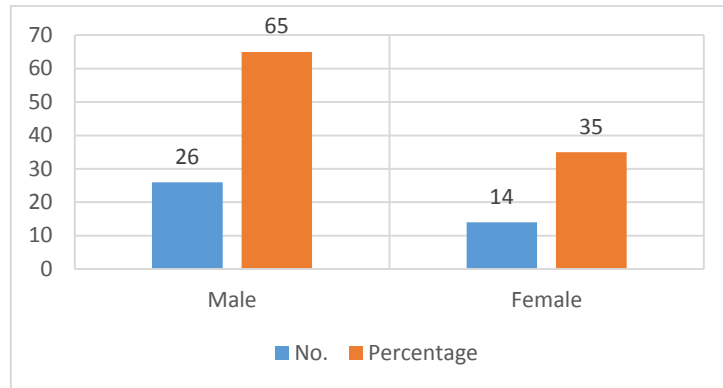


Fig. (6): A Diagram Showing the number and percentage of both male and female for this study.

Twenty patients were treated by socket shield technique and twenty patients treated by the conventional method of dental implantation. 19 out of the 20 of the patients treated by SST,

survive till the time of finishing this study, and one case fails after two weeks of placement, which means a 95% survival rate. As shown in the Figure (5).

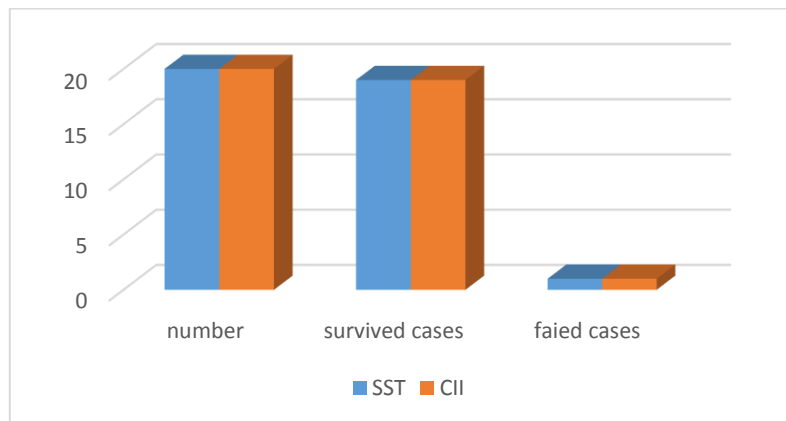


Fig. (7): A Diagram Showing the Success Rate for both socket shield technique (SST) and conventional Immediate Technique (CII) of Dental Implant.

Also, for the control group, the survival rate was 95%. After one year, 5 cases needed soft tissue graft to manage gum recession and the inadequate band of keratinized tissue that affect the aesthetic appearance.

For the cases of SST that had got success, demonstrated excellent bone stability around the implant, no pathologies related to the root shield, no radiolucency around the shield, and no space was found between the implant and the root shield in most cases with good level of marginal bone. There were 2 cases one with internal and other external shield exposure, managed by

reduction and then the soft tissue healed.

The pink esthetic score mean, of the SST on the day of starting was 12.5 and after finishing was 12.26 ± 1.04 . While for control group the mean of PES was 12.6 at the beginning and 9.63 ± 1.34 at the time of finishing of the study and that was obtained by two observers.

This study took about 12 months \pm two months and that difference of the PES between the SST and CII values was statistically significant with the Z test (p -value = 0.001). As shown in Table 3.

Table (3): Showing the Mean of Pink Esthetic Score for this Study. *Pink Esthetic Score. ** Standard deviation. ***High significant value.

Treating Strategy	PES* Day Zero	PES* After 1 Year	SD**	P-Value
SST*	12.5	12.26	1.04	0.001***
CII**	12.6	9.63	1.34	

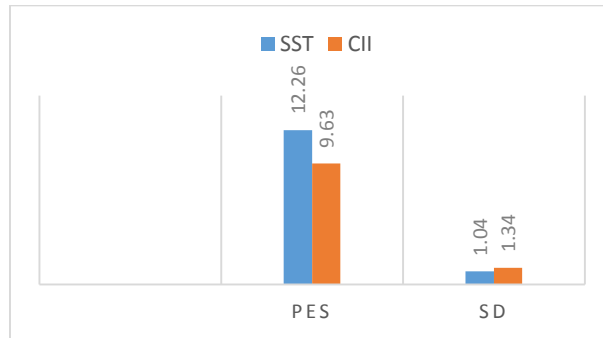


Fig. (8): The PES of both SST (blue color) and CII (red color) values after 1 year with the standard deviation of each

Also, some complications appeared in this study, and all were treated with special protocols of management. As shown in Table 4.

Table (4): Showing the number, type, and Management of Complications Appeared in this Study.

Treating Strategy	No.	Type	Management
SST*	2	External and Internal exposure of the shield	Reduction of the exposed fragment with managing of soft tissue
CII**	5	Inadequate keratinized tissue band and gum recession	Soft tissue grafts done about 1 year later

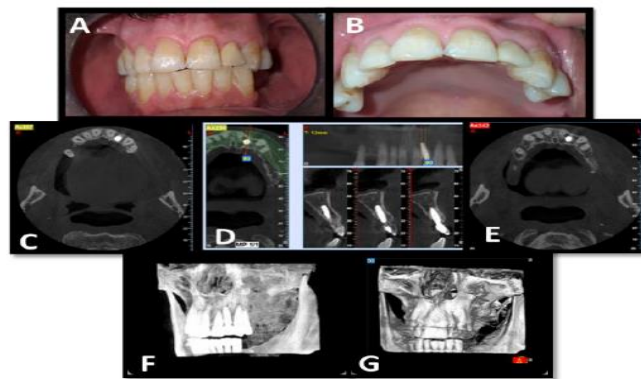


Fig. (9): Showing the clinical and radiographical evaluation of SST study case of the tooth no. 22 showing the success of that case done 11 months after implant placement; A and B: photographs showing the condition of the soft tissue. C, D, E, F and G multi views of CBCT images evaluating the implant and showing the success.

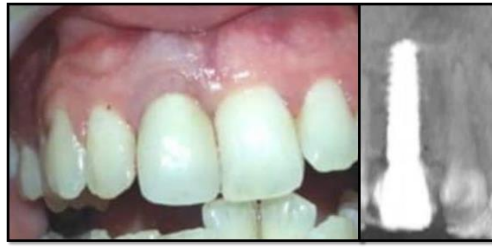

Fig. (10): clinical and radiographical image for the tooth 11 with CII after 1 year.

DISCUSSION

The immediate implant and SST of this study had high success rates as well as delayed technique. In this study the survival rate for both techniques was 95% , this result is compatible to Gluckman et al, study with survival rate 96.1 % (12).

In addition to the success rate, there was benefit of less time consumed, but still there was unpredictable esthetic outcome with the conventional immediate implant group while it was predictable with SST group, which result in more satisfaction for the implant team and the patients.

The PES for the SST in this study was 12.05, and this is compatible with the result of the study that was done by Bramanti et al, and Bäumer et al. (13, 14).

Another point to be mentioned about the result is that when we followed up the cases, none of the SST cases were indicated for soft tissue graft, while in study cases of conventional immediate implantation some cases have soft tissue loss, which suggests the need for soft tissue management.

There is additional benefit of the socket shield technique which acts as a guide for implant placement in Bucco-palatal and mesio-distal direction, as Implant placement must be done with correct three-dimensional positioning which prevents unfavorable poor esthetic and biological results, for more explanation; a more buccal position implant may cause a high risk of recession of marginal mucosa, on the other hand, an implant being placed more palatally can cause restoration overhang or an inferior emergence profile, while placement of implant in an inappropriate mesio-distal position can affect the form and size of papilla negatively, finally malpositioning

of implant in corono-apical direction can cause biological complications if placed too deeply or esthetic complication if the metal of the implant is visible (15). In addition to the correct position of implant placement, the amount of bone that is available in the planned site for insertion of the dental implant and the relation of that bone to the soft tissue play essential role in the esthetic outcome (16). The health and stability of soft tissue around the dental implants are essential for its success and long term maintenance, a wide band of two millimeters of keratinized tissue favorable to provide a soft tissue seal around natural teeth (17).

The soft tissue surrounding implants with SST was highly acceptable esthetically which can be explained by the fact mentioned before, that this technique preserves the periodontium and keep the same blood supply of natural teeth, i.e. the blood supply to the buccal bone that is from 2 sources in SST, while it is from one source in conventional immediate implant. As it is known that gingival biotype and thickness of bone is very important for the success of dental implant, so at the end if this study the result of the socket shield technique was satisfying with the presence of enough bone and gingiva that increased the esthetic outcome.

CONCLUSION

With the limitation of this study it was concluded that SST is a good modality of treatment when it is possible according to the criteria mentioned before and to be done with well experienced and skilled clinician and team, and this technique is favorable especially in the esthetic zone with advantages of decrease the total treatment time needed, more preservation of bone and the contour of soft tissue around dental implant that lead to the optimal esthetic

result ,so that the soft tissue related to the placed dental implant get closure to natural tooth appearance, which make this technique the superior in that point, in addition to that mostly there will be no need for other correcting and repairing procedures like ridge preservation, augmentation or soft tissue grafts that increase the visits and cost of the implant restoration, and with a high success rate as the other techniques in addition presence of root shield technique act as a guide for correct placement of dental implant in Bucco-palatal and mesio_distal direction .

REFERENCES

- Ortega-Martínez, J., Pérez-Pascual, T., Mareque-Bueno, S., Hernández-Alfaro, F., Ferrés-Padró, E., 2012. Immediate implants following tooth extraction. A systematic review. *Medicina Oral, Patología Oral y Cirugía Bucal* 17, e251. doi.org/10.4317/medoral.17469.
- Miltiadis E. Mitsias, Konstantinos D. Siompas, Georgios A. Kotsakis, Scott D. Ganz, Carlo Mangano, and Giovanna Iezzi, “The Root Membrane Technique: Human Histologic Evidence after Five Years of Function,” *BioMed Research International*, vol. 2017, Article ID 7269467, 8 pages, 2017. https://doi.org/10.1155/2017/7269467.
- Esteve-Pardo, G., Esteve-Colomina, L., 2018. Clinical Application of the Socket-Shield Concept in Multiple Anterior Teeth. *Case Reports in Dentistry* 2018, 1–7. https://doi.org/10.1155/2018/9014372.
- Craddock, H.L., 2009. Consequences of Tooth Loss: 1. The Patient Perspective – Aesthetic and Functional Implications. *Dental Update* 36, 616–619. https://doi.org/10.12968/denu.2009.36.10.616.
- Nevins M, Camelo M, De Paoli S, et al. A study of the fate of the buccal wall of extraction sockets of teeth with prominent roots. *Int J Periodontics Restorative Dent* 2006; 26:19–29.
- Viña-Almunia, J., Candel-Martí, M.E., Cervera-Ballester, J., García-Mira, B., Calvo-Guirado, J.L., Peñarrocha-Oltra, D., Peñarrocha-Diago, M., 2013. Buccal bone crest dynamics after immediate implant placement and ridge preservation techniques: review of morphometric studies in animals. *Implant Dent* 22, 155–160. http://doi.org/10.1097/ID.0b013e318287a947.
- Choi, Sunyoung, In-Sung Yeo, Sung-Hun Kim, Jai-Bong Lee, Chan Wook Cheong, and Jung-Suk Han. 2015. “A Root Submergence Technique for Pontic Site Development in Fixed Dental Prostheses in the Maxillary Anterior Esthetic Zone.” *Journal of Periodontal & Implant Science* 45 (4): 152–55. https://doi.org/10.5051/jpis.2015.45.4.152.
- Vanhoutte, V., Rompen, E., Lecloux, G., Rues, S., Schmitter, M., Lambert, F., 2014. A methodological approach to assessing alveolar ridge preservation procedures in humans: soft tissue profile. *Clin Oral Implants Res* 25, 304–309. https://doi.org/10.1111/clr.12144.
- Hürzeler, M.B., Zuhr, O., Schupbach, P., Rebele, S.F., Emmanouilidis, N., Fickl, S., 2010. The socket-shield technique: a proof-of-principle report. *J. Clin. Periodontol.* 37, 855–862. https://doi.org/10.1111/j.1600-051X.2010.01595.
- Kumar, Payal Rajender, and Udatta Kher. 2018. “Shield the Socket: Procedure, Case Report and Classification.” *Journal of Indian Society of Periodontology* 22 (3): 266–72. doi.org/10.4103/jisp.jisp_78_18.
- Gharpure, A.S., Bhatavadekar, N.B., 2017. Current Evidence on the Socket-Shield Technique: A Systematic Review. *Journal of Oral Implantology*. doi.org/10.1563/aaid-joi-D-17-00118.

- Gluckman H, Salama M, Du Toit J. A retrospective evaluation of 128 socket-shield cases in the esthetic zone and posterior sites: Partial extraction therapy with up to 4 years follow-up. *Clin Implant Dent Relat Res.* 2017; 00:1–8. <https://doi.org/10.1111/cid.12554>.
- Bramanti, E., Norcia, A., Cicciù, M., Matakana, G., Cervino, G., Troiano, G., Zhurakivska, K., Laino, L., 2018. Postextraction Dental Implant in the Aesthetic Zone, Socket Shield Technique Versus Conventional Protocol. *J Craniofac Surg* 29, 1037–1041.
- Bäumer D, Zuhr O, Rebele S, Hürzeler M. Socket Shield Technique for immediate implant placement – clinical, radiographic and volumetric data after 5 years. *Clin. Oral Impl. Res.* 28, 2017, 1450–1458 doi: 10.1111/clr.13012.
- Darby, I., Chen, S.T., Buser, D., 2009. Ridge preservation techniques for implant therapy. *Int J Oral Maxillofac Implants* 24 Suppl, 260–271.
- Mezzomo, L.A., Shinkai, R.S., Mardas, N., Donos, N., 2011. Alveolar ridge preservation after dental extraction and before implant placement: a literature review. *Revista Odontologia Ciênci* 26, 77–83. <https://doi.org/10.1590/S1980-65232011000100017>.
- Cho, S.-C., Froum, S.J., Kamer, A.R., Loomer, P.M., Romanos, G., Demiralp, B., 2015. Implants in the Anterior Maxilla: Aesthetic Challenges. *International journal of dentistry* 2015, 152420. doi.org/10.1155/2015/152420.

تهکنیکا سوکیت شیلد یا چاندنا ددانا ل ناچا جوانی بربکا نهرخاندنا کلینیکی و تیژکان

بوخته

پیداویستین سهرهکی و نارمانج: تهکنیکا سوکیت شیلد نهوه دهمی کولیلکا ددانی دهیلن د دیوارئ سوکیت دا بهری چاندنا ددانا. نهگه رئ هیلانا کولیلکا ددانی نهوه دا جانی نهوه دا جهین دهوربهری ددانا وهک بهری بزقرن.

مه ره ما لیگه رینئ: نهرخاندنا رولئ هیلانا کولیلکا ددانا د پاراستنا جانی و کارئ وی جهی نهوی چاندنا ددانا لئ هاتیه کرن.

ربکین هاتینه کارئینان دلگه رینیدا: 40 نهخوش هاتنه تومار کرن بربکه کا بی شیواز. بیست ژ نهخوشان ددانین وان هاتینه چاندن بربکا تهکنیکا سوکیت شیلد و بیستین دی بربکا که قن یا راسته وخو. پشتی هنگی دیقچون یا هاتیه کرن لسهر ههردوو گروپان و نهرخاندنا وان یا هاتیه کرن لسهر ناستئ ساخله میا چاندنئ و ناستئ جانی پیقازی یا چه رمئ نه رم یا گریدای بچاندنا ددانا و تیشکین PA و O.P.G و دگه ل تیشکین CBCT نهوین هاریکاریئ دکهن د دیارکرنا خرابیئ د ههستیان دا و زهختئ وان ددانین هاتینه چاندن.

نهجام: ژهره گروپه کی بهس کریارا ئیک نهخوشی سهرنه که فت. ربژه یا سهرکه فتنئ 95% بوو. و بربکا نهرخاندنا کلینیکی یا ناستئ جانی پیقازی دیاربوو دو تهکنیکا سوکیت شیلد نرخئ پتر ئینا بو نیزکیا نرخئ ددانین سروشتی کو 12.26 بوو، بهلئ نرخئ ربکا که قن نرخه کئ کیمتر ئینا سهر ناستئ جانی پیقازی کو نرخئ وی 9.63 بوو. و نهجامین ربکا چاندنا ددانا یا که قن هه می وهک ئیک نه ده رکه فتن و هندهک ژ نهخوشان پشتی ساله کئ پیدقی هه بوو ب گرافته کی بو چیکرنا نه و زهره رئ هاتیه کرن ل ناچا جوانیئ. بهلئ پیویستی نه بو وی تشتی د تهکنیکا سوکیت شیلد دا.

بوخته: تهکنیکا سوکیت شیلد بو چاندنا ددانا چیدبیت باشتربیت بو هیلانا جانی سروشتی یا جهی چاندنئ. نهف تهکنیکه باشتربین نهجامی ددهت بو هیلانا جانیئ بهلئ دقینن نه و پزیشکی قئ تهکنیکئ بکاربیت یئ بههست بیت دا نه خرابیئ ژقئ نهخوشیئ ده رکه قن نه هیلیت. وشین دیارکه ر: سوکیت شیلد، نه مانا ههستیان، ناچا جوانیئ، ناستئ پیقازی یئ جانیئ

تقنية سوكت شيلد (Socket Shield) لزراعة الاسنان في المنطقة الجمالية, تقييم سريري وبواسطة صور الاشعه

الخلاصه

معلومات خلفية والاهداف : تقنية سوكت شيلد او القلع الجزئي للسن عندما يترك شظية الجذر في جدار السنخ قبل زرع الاسنان. الغاية من الابقاء على الشظية هو للحفاظ على الجمال الطبيعي في منطقة زرع الاسنان.

الغاية من الدراسة : لتقييم دور الابقاء على الشظية الجذرية في الحفاظ على جمالية وفعالية المنطقة التي اجري العملية عليها.

طرق ومواد البحث : تم تسجيل أربعين مريضاً بشكل عشوائي. تم اجراء عملية زرع الاسنان بتقنية سوكت شيلد في عشرين من الحالات والعشرين الاخرين تم اجراء العملية التقليدية لزراعة الاسنان الفورية . بعد ذلك تم متابعة وتقييم كلا من المجموعتين من ناحية سلامة الزرع درجة الجمالية الوردي للانسجة الرخوة سريريا، وتقييم بواسطة صور الأشعة مثل التصوير المحيطي PA والاشعات البانورامية OPG والاشعات المقطعي المخروطي CBCT للمساعدة على ايجاد اي اضرار او عيوب في الاسنان وسماكة العظم الشدقي للسن في المنطقة التي تم الزرع فيها.

النتائج : فشلت حالة واحدة من كلا المجموعتين. نسبة العامة للنجاح كانت 95%. التقييم السريري للانسجة الرخوة البنفسجية في تقنية سوكت شيلد لزراعة الاسنان اظهر قيمة اكبر من الاسنان الطبيعية 12,26 في حينما في العملية التقليدية المباشرة لزراعة الاسنان كان هناك نقص في درجة الانسجة الرخوة البنفسجية 9,63. نتائج العملية التقليدية لزراعة الاسنان كانت غير متوقعة, وبعض من الحالات احتاجوا لعملية تطعيم الانسجة الرخوة لاصلاح الضرر الذي اصيب الجمال الطبيعي بعد سنة من العملية وهذا لم يكون مطلوباً في تقنية مقبس الترس.

الاستنتاج : تقنية سوكت شيلد لزراعة الاسنان قد يكون خياراً مناسباً للحفاظ على الجمال الطبيعي في منطقة الزرع. هذه التقنية تمنح النتيجة الامثل للحفاظ على الجمال ولاكنها تحتاج ان يجريها جراح خبير لمنع المضاعفات المتعلقة بهذه التقنية.

الكلمات الدالة : سوكت شيلد, فقدان العظام, المنطقة الجمالية, درجة الجمالية الوردي.